

# Vascular Access for Hemodialysis

Larry A. Scher, M.D.

Professor of Clinical Surgery

Division of Vascular Surgery

Montefiore Medical Center

Albert Einstein College of Medicine

Bronx, New York

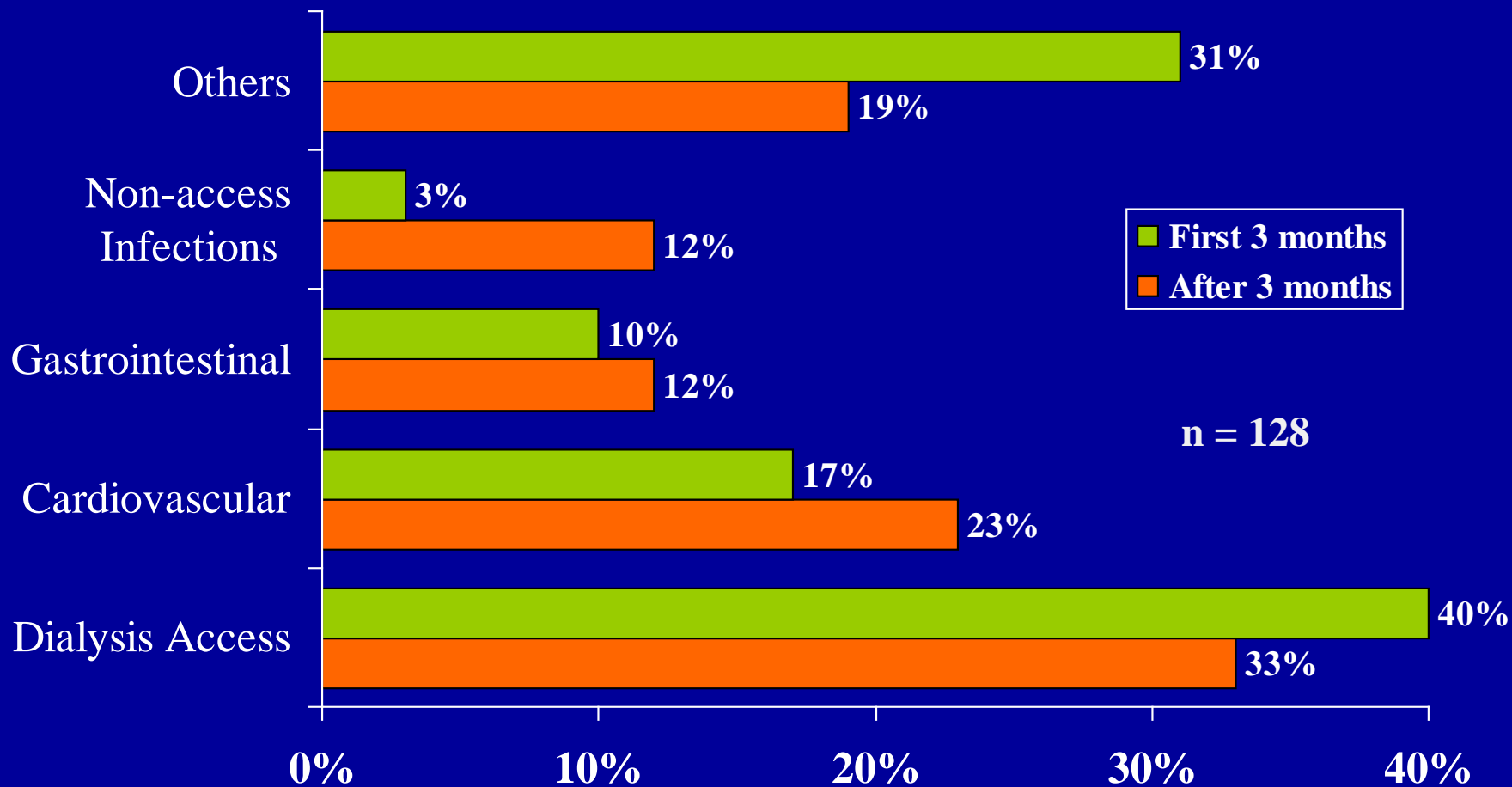


2013 NY Regional Meeting, September 29, 2013

# **Update on Hemodialysis Access Surgery**

- **Overview: K-DOQI and Fistula First**
- **Strategy for sequential access placement**
- **AV fistula, AV graft, HeRO graft**
- **Fistula maturation**
- **Complications**

# Causes of Hospitalization in New ESRD Patients Receiving Hemodialysis





# Vascular Access: Europe vs. United States

## *Dialysis Outcomes and Practice Patterns Study*




- **6400 hemodialysis patients in Europe (France, Germany, Italy, Spain and UK) and United States**
- **80 % AVF Europe vs. 24% US in prevalent patients (2002 data)**
- **Initial hemodialysis access:**
  - **Europe: 66% AVF, 2% AVG, 31% catheter**
  - **US: 15% AVF, 24% AVG, 60% catheter**



**Goal: Increase the percentage of hemodialysis patients using AV fistulas to 66% by 2009**

**Order or preference for AV fistulae**  
**Wrist (radiocephalic)  
AV fistula**  
**Elbow (brachiocephalic)  
AV fistula**



## Guidelines on topics for management of patients with chronic kidney disease including vascular access

- **Clinical Practice Guidelines for Vascular Access, Update 2006**
- **Guideline 1.** Patient Preparation for Permanent Hemodialysis Access
- **Guideline 2.** Selection and Placement of Hemodialysis Access
- **Guideline 3.** Cannulation of Fistulae and Grafts and Accession of Hemodialysis Catheters and Port Catheter Systems
- **Guideline 4.** Detection of Access Dysfunction: Monitoring, Surveillance, and Diagnostic Testing
- **Guideline 5.** Treatment of Fistula Complications
- **Guideline 6.** Treatment of Arteriovenous Graft Complications
- **Guideline 7.** Prevention and Treatment of Catheter and Port Complications
- **Guideline 8.** Clinical Outcome Goals

## DOQI Guideline 2: **Selection of Permanent Vascular Access and Order of Preference for Placement of AV Fistulae**

- Order or preference for AV fistulae
  - Wrist (radiocephalic) primary AV fistula
  - Elbow (brachiocephalic) AV fistula
- If either fistula not possible
  - AV graft with synthetic material
  - Transposed brachial basilic fistula
- Cuffed venous catheters should be discouraged as permanent vascular access





- **Coalition to increase the use of AV fistulas for hemodialysis**

- **Goal: Increase the percentage of hemodialysis patients using AV fistulas to 66% by 2009**

- **As of 2010, 57% of hemodialysis patients use AV fistulas, which is a 78% increase since the initiative began in 2003**

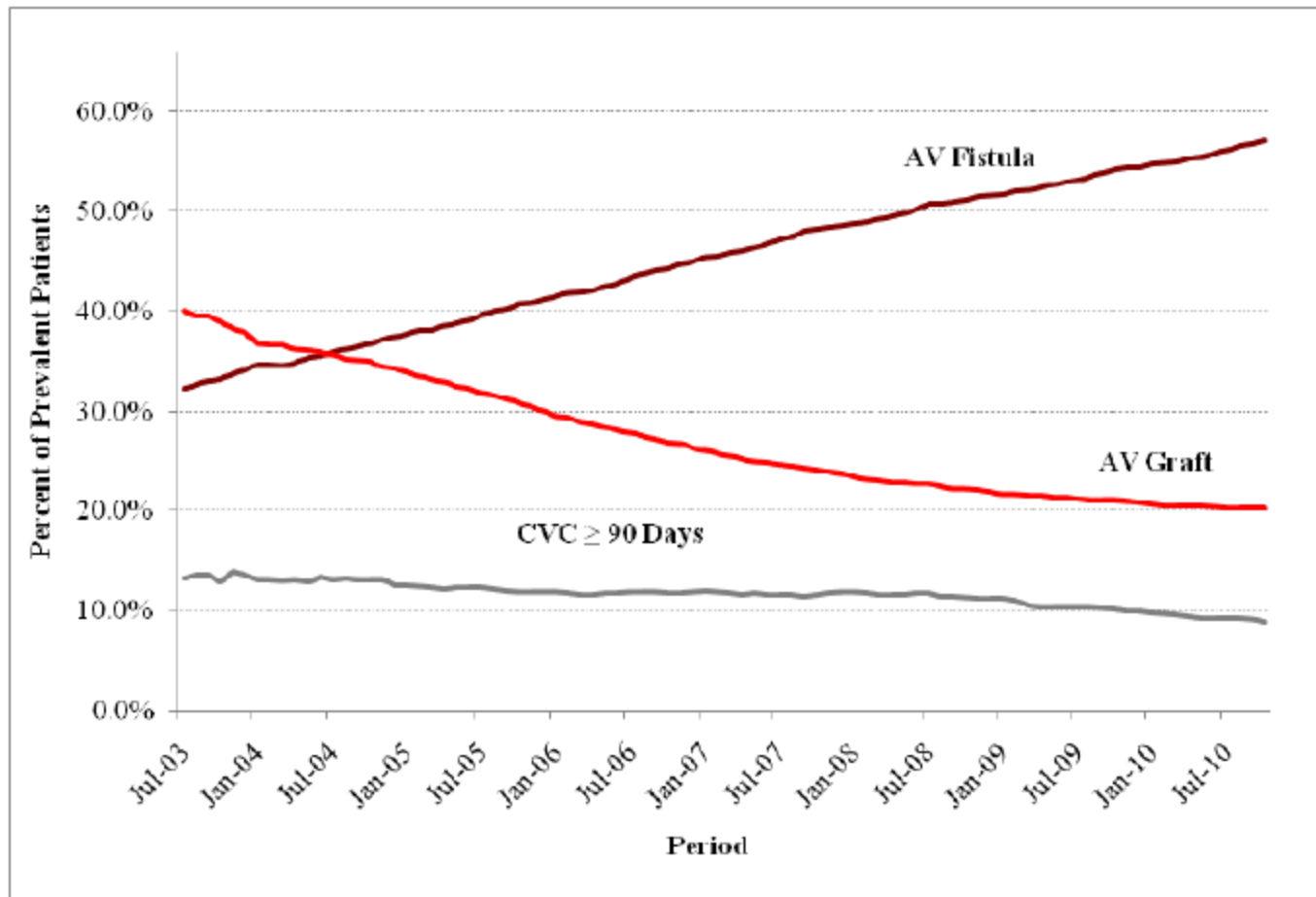
# Prevalent US Data

	<b>AVF Use</b>	<b>AVF Placed</b>	<b>Graft Use</b>	<b>CVC &gt; 90 days</b>	<b>CVC Use Total</b>
<b>July 2003</b>	<b>32.2</b>	<b>38.4</b>	<b>40.1</b>	<b>13.3</b>	<b>26.9</b>
Jan 2004	34.6	40.8	36.7	13.1	27.1
Jan 2005	37.8	44.7	33.9	12.6	27.8
Jan 2006	41.5	49.5	29.5	11.9	28.4
Jan 2007	48.3	53.6	26.0	12.0	28.2
Jan 2008	48.8	56.6	23.4	11.9	27.4
Jan 2009	51.8	59.4	21.7	11.2	26.3
<b>Feb 2010</b>	<b>54.8</b>	<b>62.7</b>	<b>20.6</b>	<b>9.7</b>	<b>24.4</b>

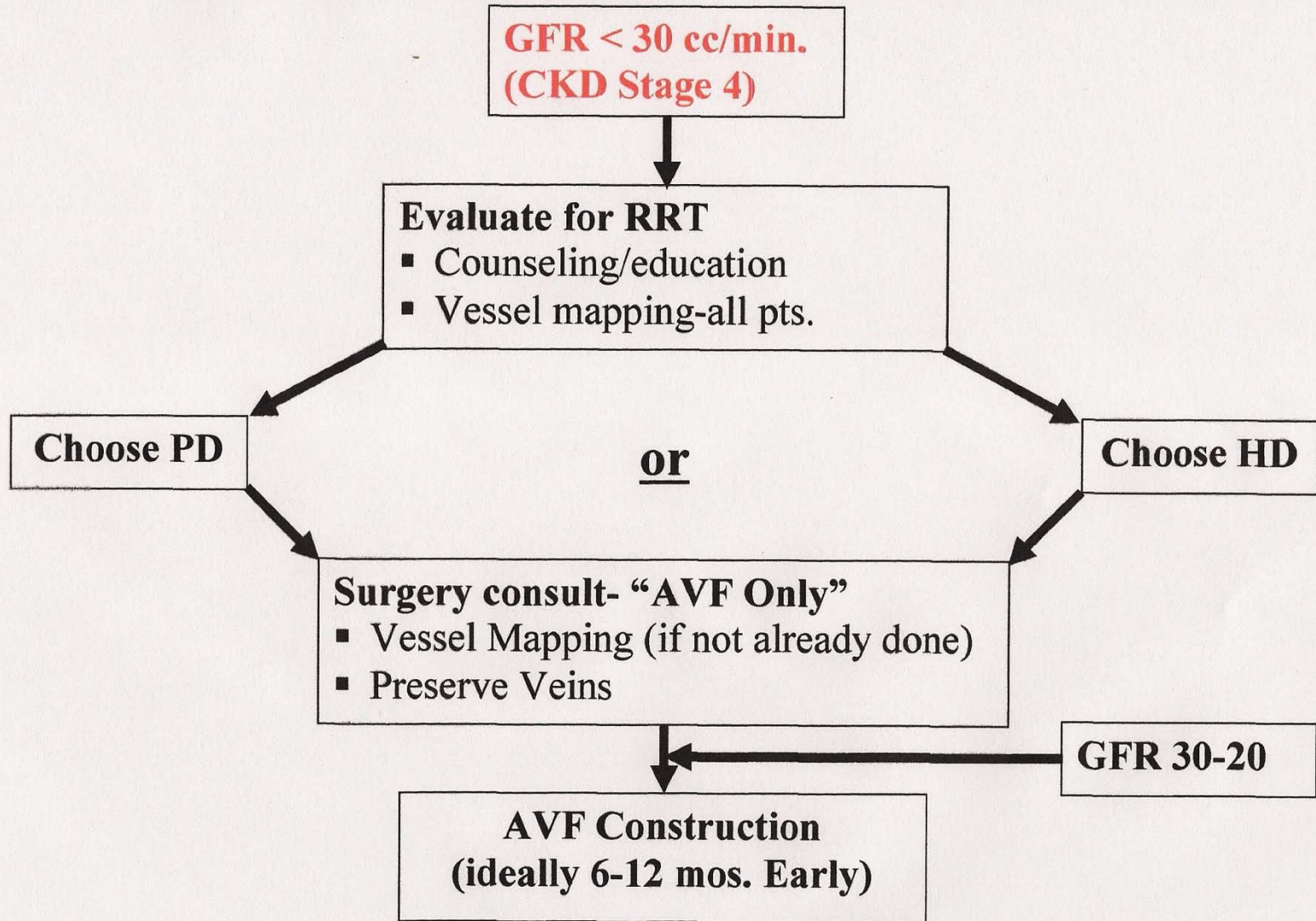
# National AV Fistula Rate Reaches 57.5% in December 2010

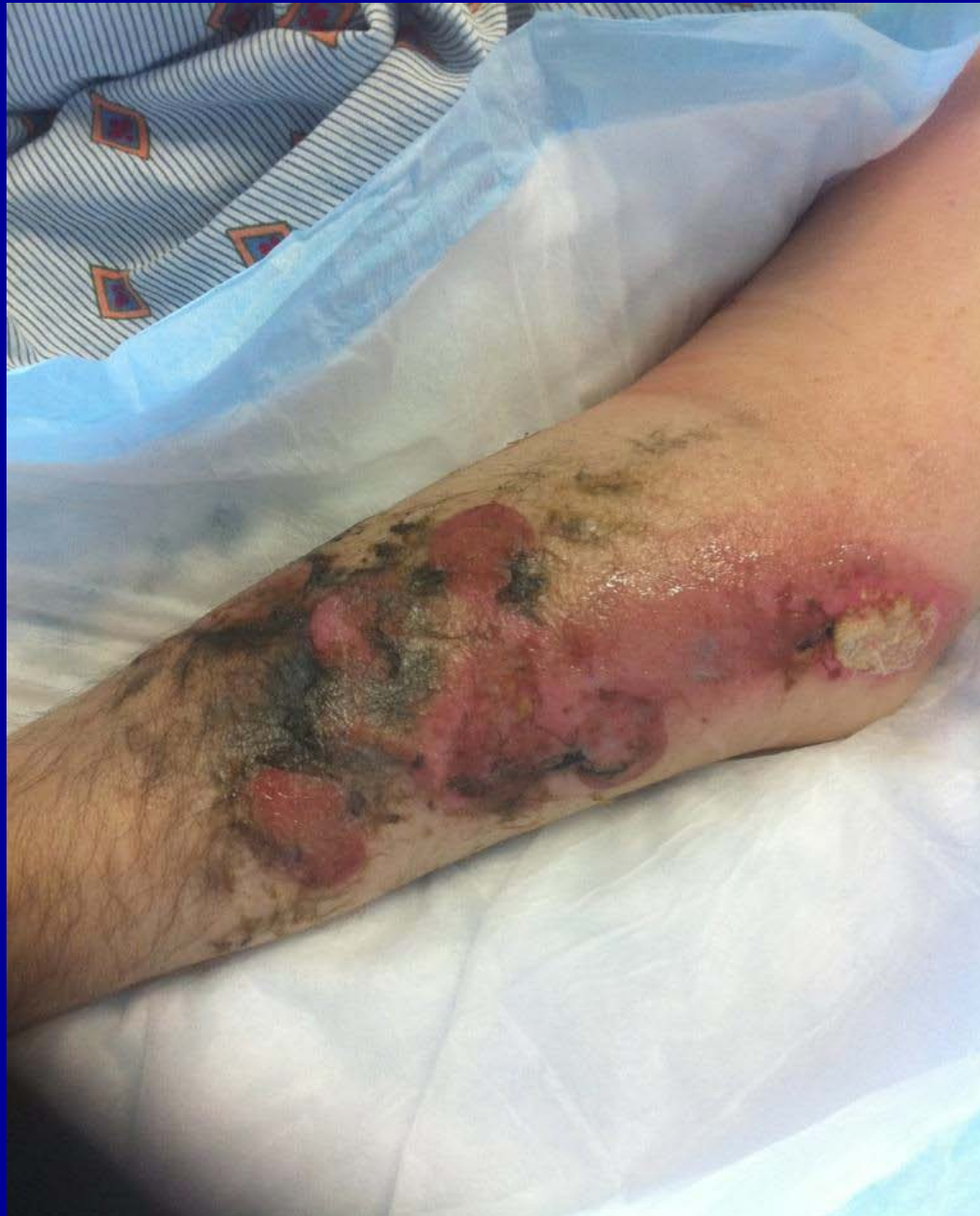## 2010 Fistula First Annual Report

Figure 3: U.S. Trends in AV Fistula<sup>1</sup>, AV Graft<sup>2</sup> and CVC  $\geq$  90 Days<sup>3</sup> Use, July 2003 through October 2010<sup>4</sup>



# CKD Stage 4 Vascular Access/AVF Plan



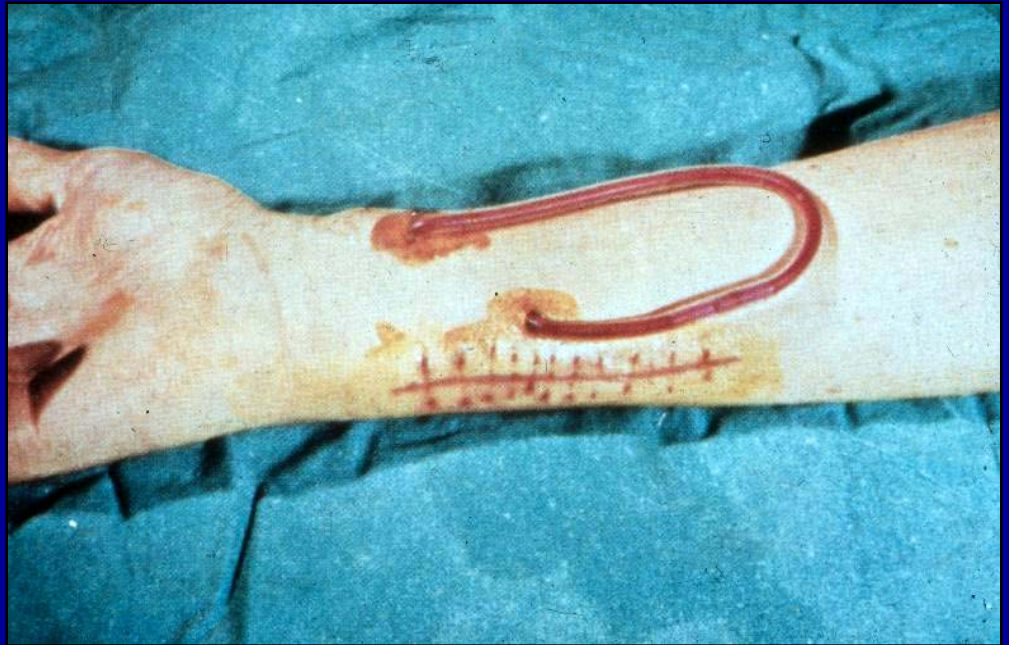


# **Principles of hemodialysis access surgery**

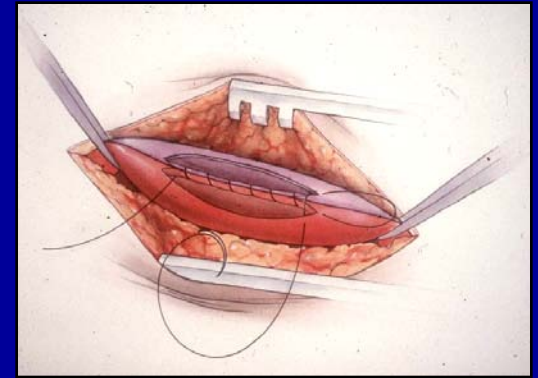
- **Strategy for long-term sequential access placement**
- **Autogenous preferred**
- **Evaluation of arterial inflow and venous outflow**
- **Upper extremity over lower extremity**
- **Nondominant arm over dominant arm**
- **Forearm over upper arm**
- **Type of prosthetic graft material**
- **Cuffed venous catheters discouraged**



**Belding Scribner**  
**1921-2003**



# Chronic hemodialysis using venipuncture and a surgically created arteriovenous fistula



Michael J. Brescia, M.D., James  
E. Cimino, M.D., Kenneth  
Appel, M.D. and Baruch J.  
Hurwich, M.D.

NEJM 275:1089-1092, 1966.





# James E. Cimino (1928-2010)

## MILESTONES IN NEPHROLOGY

*To Larry - many thanks for your appreciation of our work. Best wishes*

J Am Soc Nephrol 10: 193-199, 1999

## CHRONIC HEMODIALYSIS USING VENIPUNCTURE AND A SURGICALLY CREATED ARTERIOVENOUS FISTULA\*

MICHAEL J. BRESCIA, M.D.,† JAMES E. CIMINO, M.D.,‡ KENNETH APPEL, M.D.,§  
AND BARUCH J. HURWICH, M.D.†

BRONX, NEW YORK

with comments by

JAMES E. CIMINO and BELDING H. SCRIBNER

Reprinted from N. Engl. J. Med. 275: 1089-1092, 1966

*Jack Cimino  
AKA Jim*

**T**HE success of chronic hemodialysis in terminal renal failure depends on repeated access to blood vessels that will provide a continuous flow of up to 250 to 300 ml. per minute.

A technic was developed for the permanent implantation of cannulas into an artery and vein of the forearm. Between dialyses, patency of these blood vessels depends on maintaining circulation between artery and vein by means of a Teflon-Silastic loop, creating an external arteriovenous fistula. The surgical technic required for the successful implantation of these catheters has been described.<sup>1,2</sup> This prosthesis is now

### AUTHOR COMMENTARY



James E. Cimino

Calvary Hospital, Bronx, New York

# What is the best access for hemodialysis?

As we approach the 50<sup>th</sup> anniversary of the initial description of the AV fistula, it still remains the best access for hemodialysis.

# Primary Arteriovenous Fistula

- Advantages

- superior patency
- fewer complications (infection, arterial steal)
- easy revision
- single anastomosis

- Disadvantages

- frequent thrombosis of forearm veins
- delayed maturation (4-6 weeks)
- difficult cannulation
- ? lower flow rates

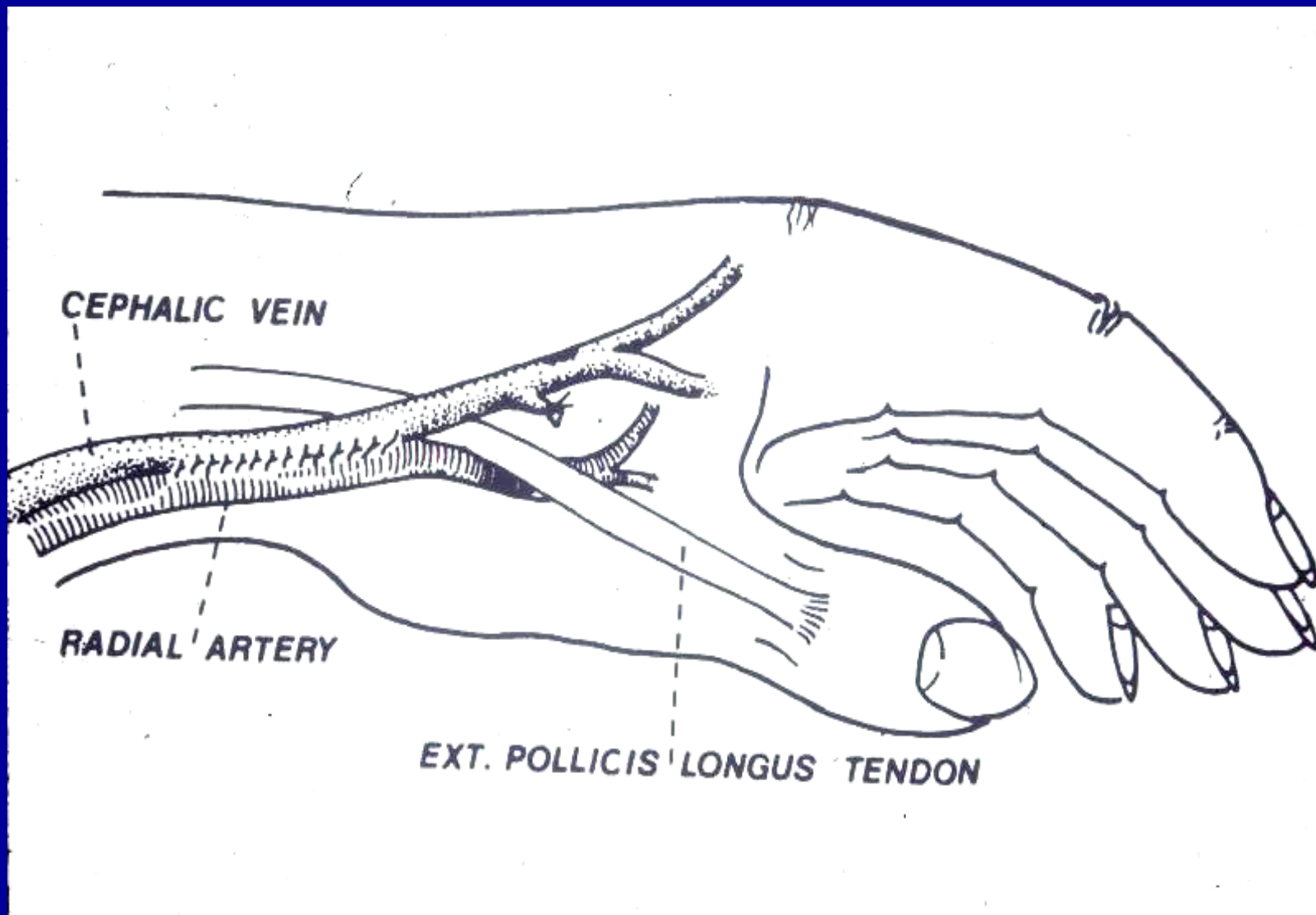
# Evaluation of Sites for AV Fistula

- **Physical examination / duplex ultrasound**
- **Suitability of vein**
  - **Diameter above 2.5 mm. for AV fistula**
  - **Diameter above 4.0 mm. for AV graft**
  - **Continuity with deep and central vein**
  - **Absence of stenosis**
- **Suitability of artery**
  - **Arterial lumen greater than 2.0 mm.**
  - **Absence of obliterating calcification**
  - **Patency of palmar arch (?)**

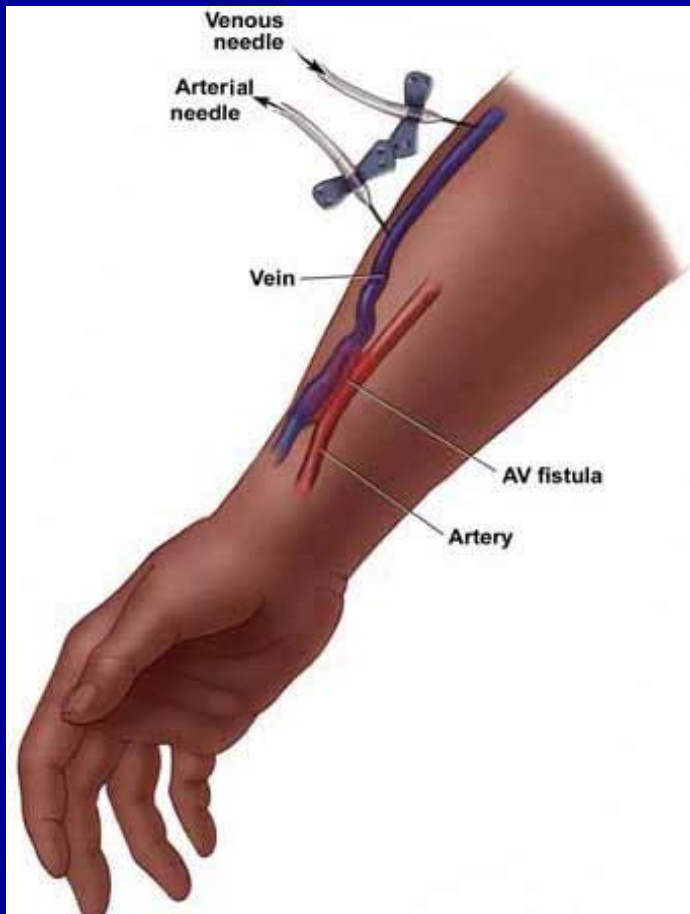
# Sites for AV Fistula

- radiocephalic
- snuffbox
- antecubital (brachiocephalic)
- transposed basilic vein
  - upper arm
  - forearm

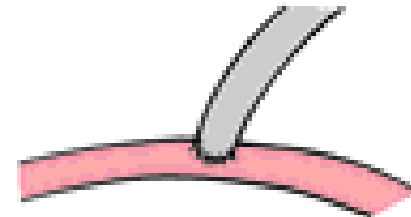
# Snuffbox AV Fistula



# Radiocephalic AV Fistula

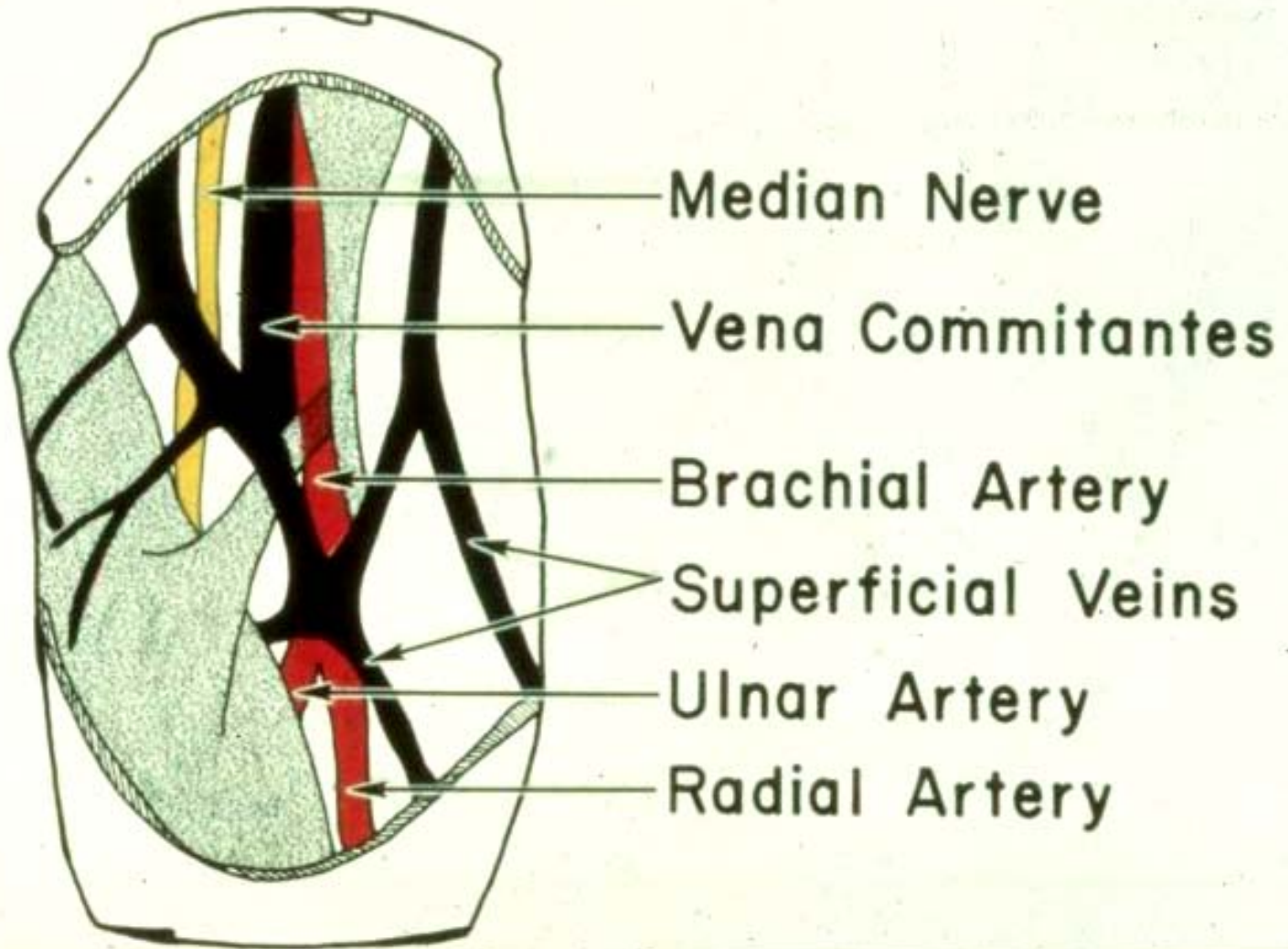


Side-to-side



Side of artery to  
end of vein

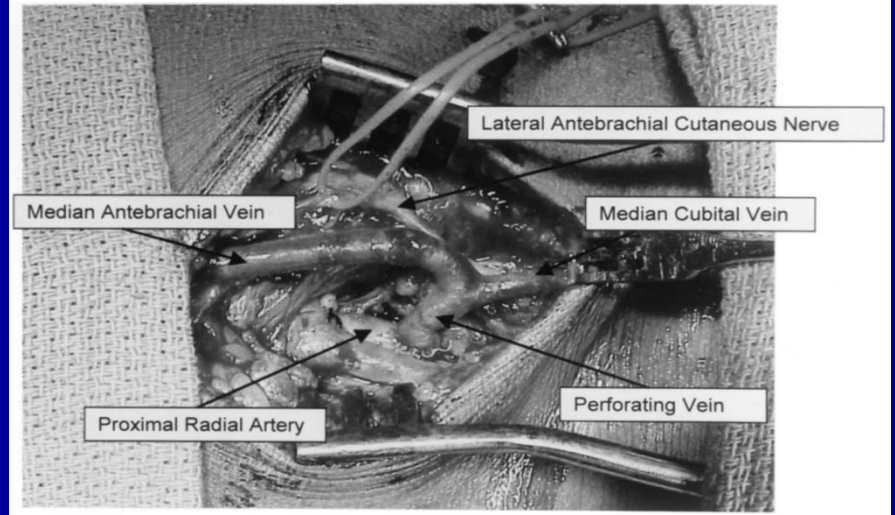
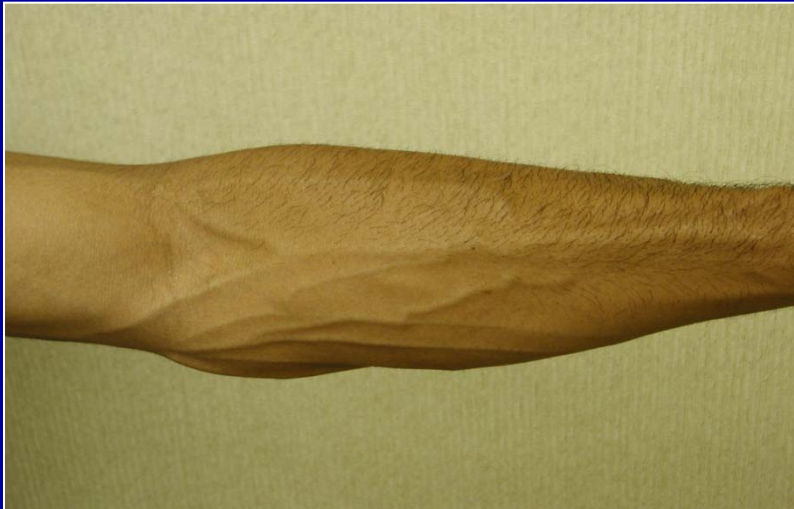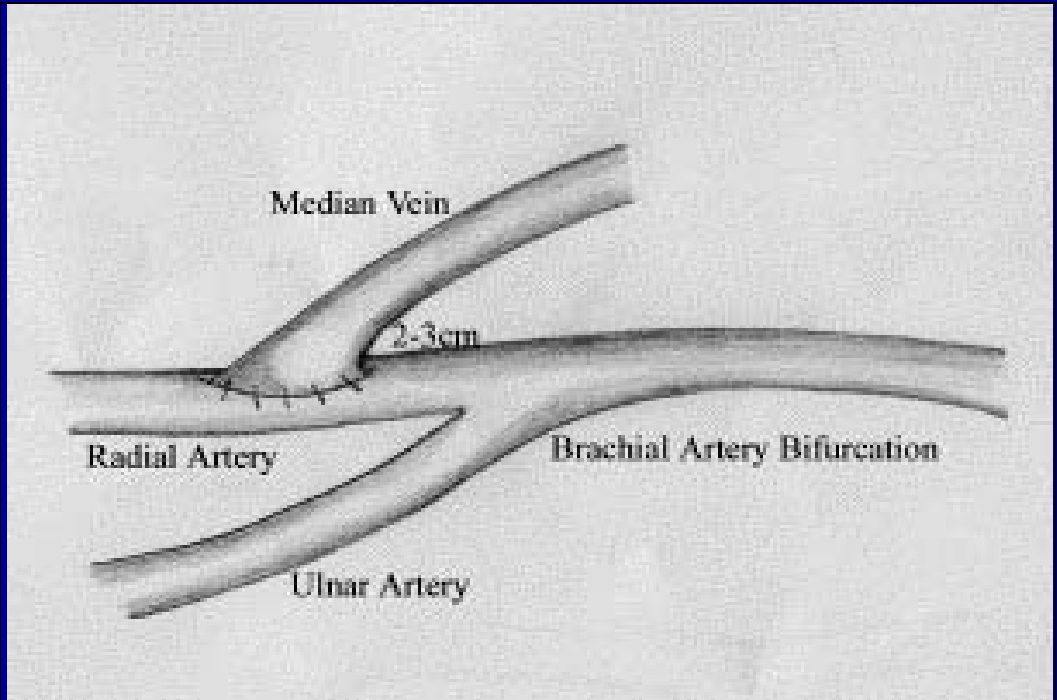
# ANTECUBITAL FOSSA





# Proximal Radial Artery Fistula

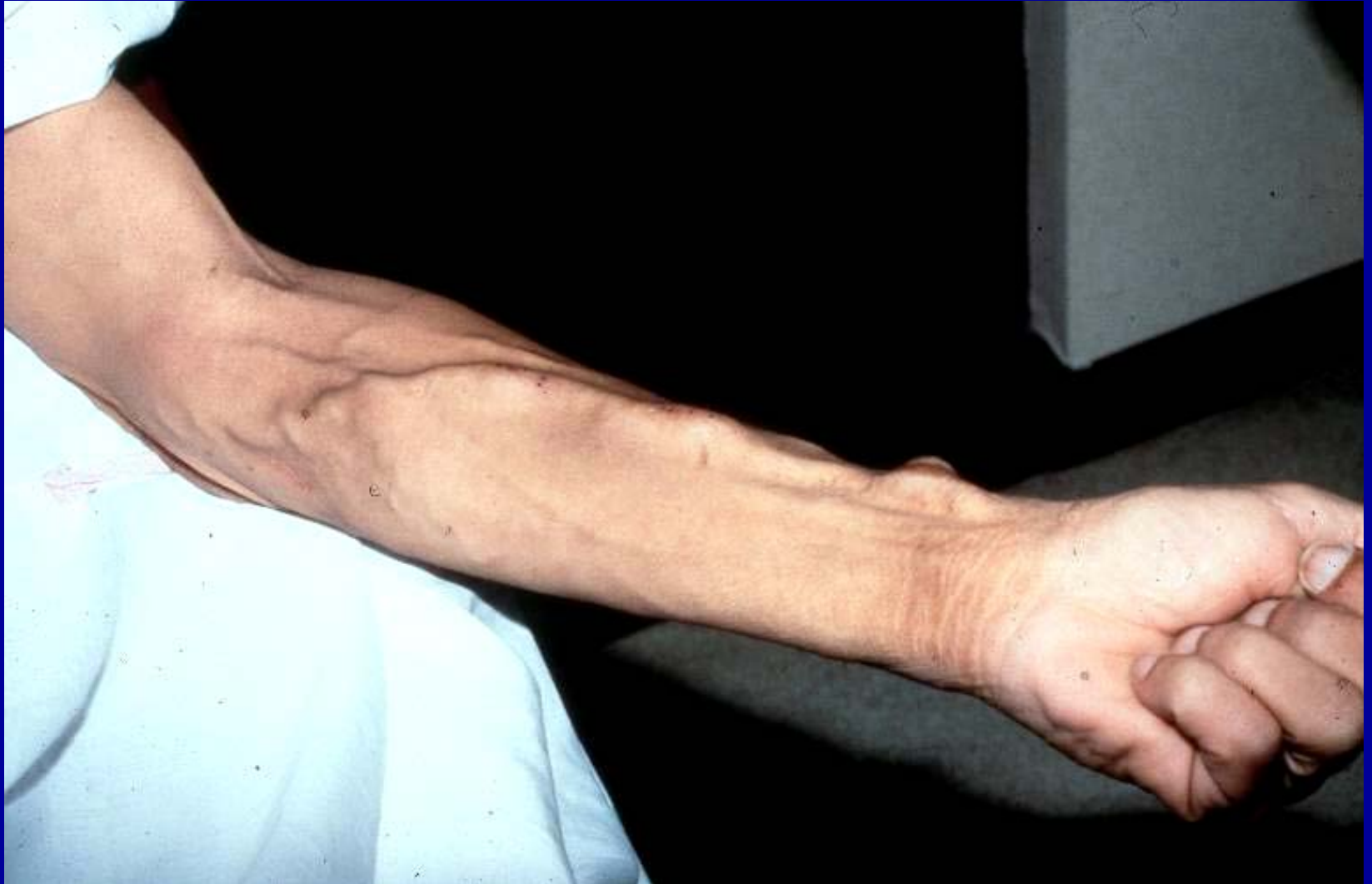- Alternative when wrist fistula not feasible
- Adequate arterial inflow but reduced risk of steal compared to brachial artery fistulas
- Venous anatomy critical – deep perforating branch of median antebrachial vein
- Excellent patency rates



# Forearm basilic vein transposition

- Silva et al. (JVS 1997;26:981-6)
- Duplex evaluation of forearm arteries and veins
- Increased utilization of autogenous veins for AV access with transposition techniques

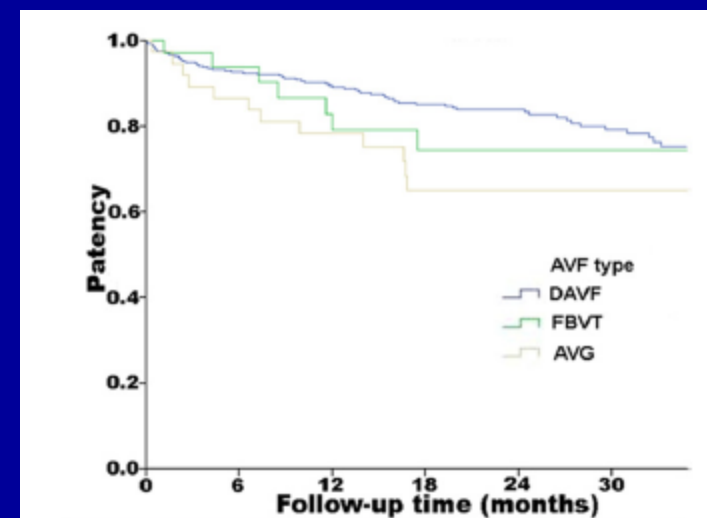
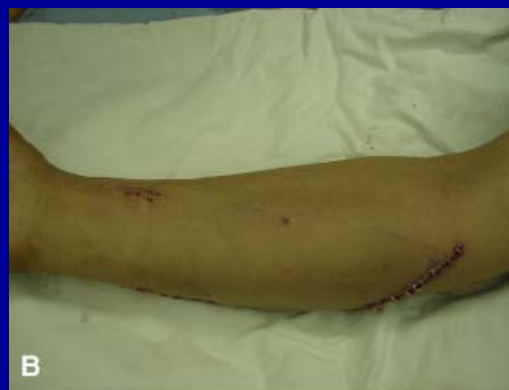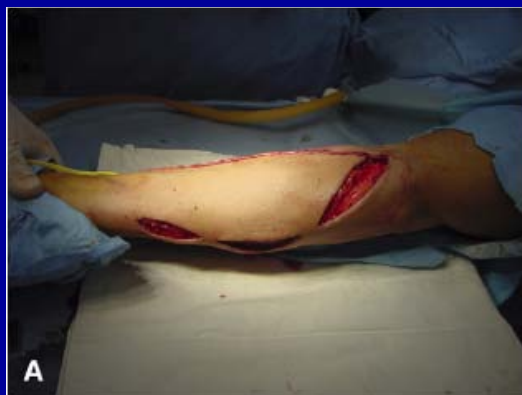# Forearm Basalic Vein Transposition



# Evaluation of the efficacy of the forearm basilic vein transposition arteriovenous fistula

Hae-Jung Son, MD, Seung-Kee Min, MD, PhD, Sang-Il Min, MD, Yang Jin Park, MD, Jongwon Ha, MD, PhD, and Sang Joon Kim, MD, PhD, *Seoul, Korea*

(*J Vasc Surg* 2010;51:667-72.)



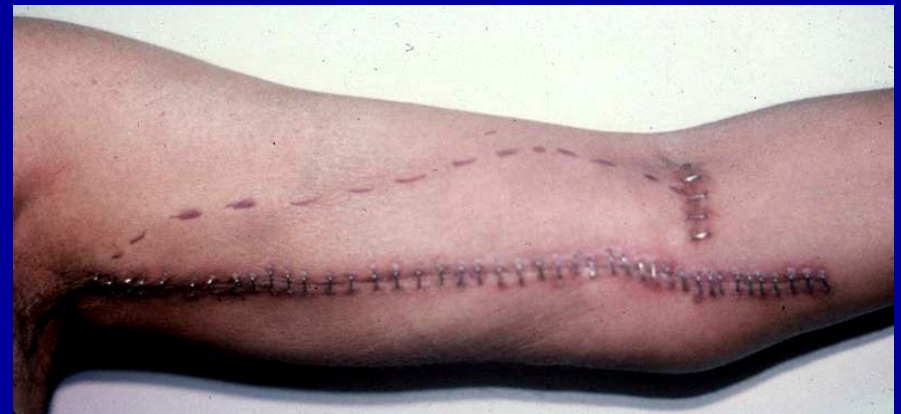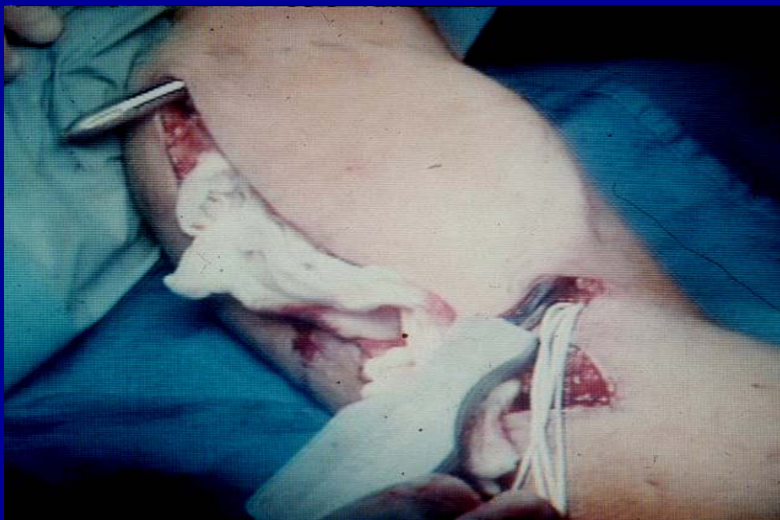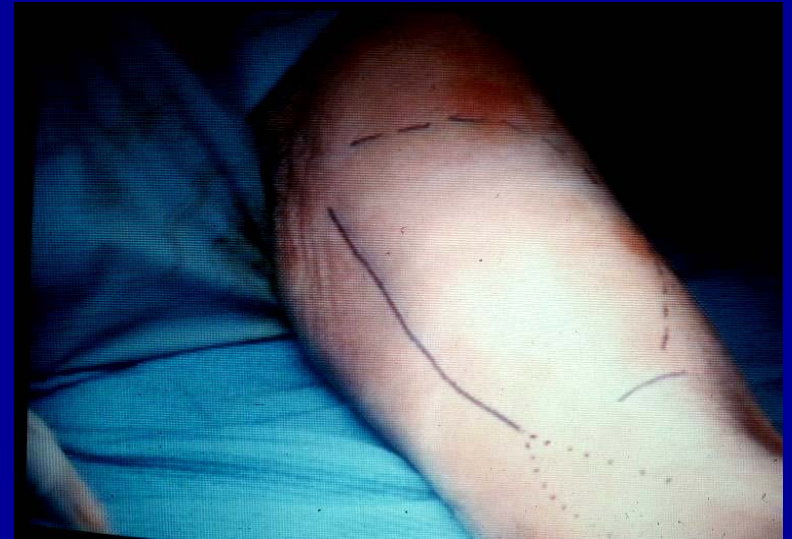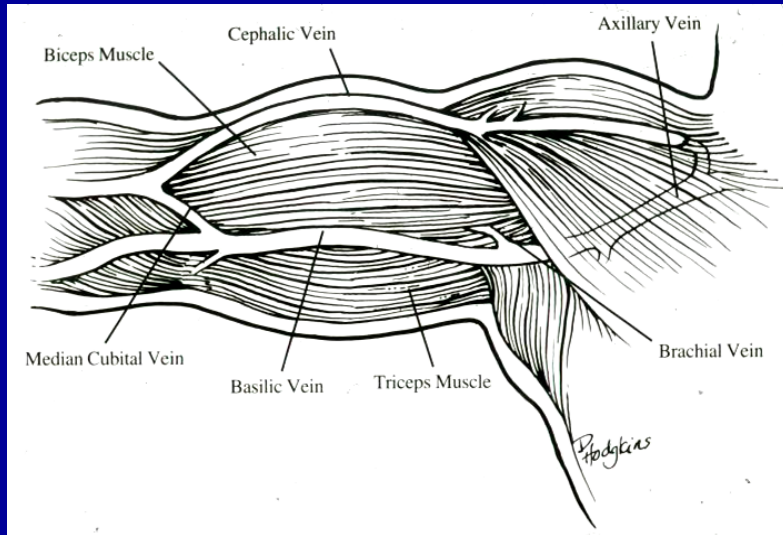
Patient at risk						
	0	6	12	18	24	30
DAVF	309	273	227	157	95	
FBVT	26	21	16	10	6	
AVG	32	27	16	6	1	

Fig 4. Kaplan-Meier curves show of secondary patency rates for direct arteriovenous fistulas (DAVFs), forearm basilic vein transpositions (FBVTs), and prosthetic arteriovenous grafts (AVGs).

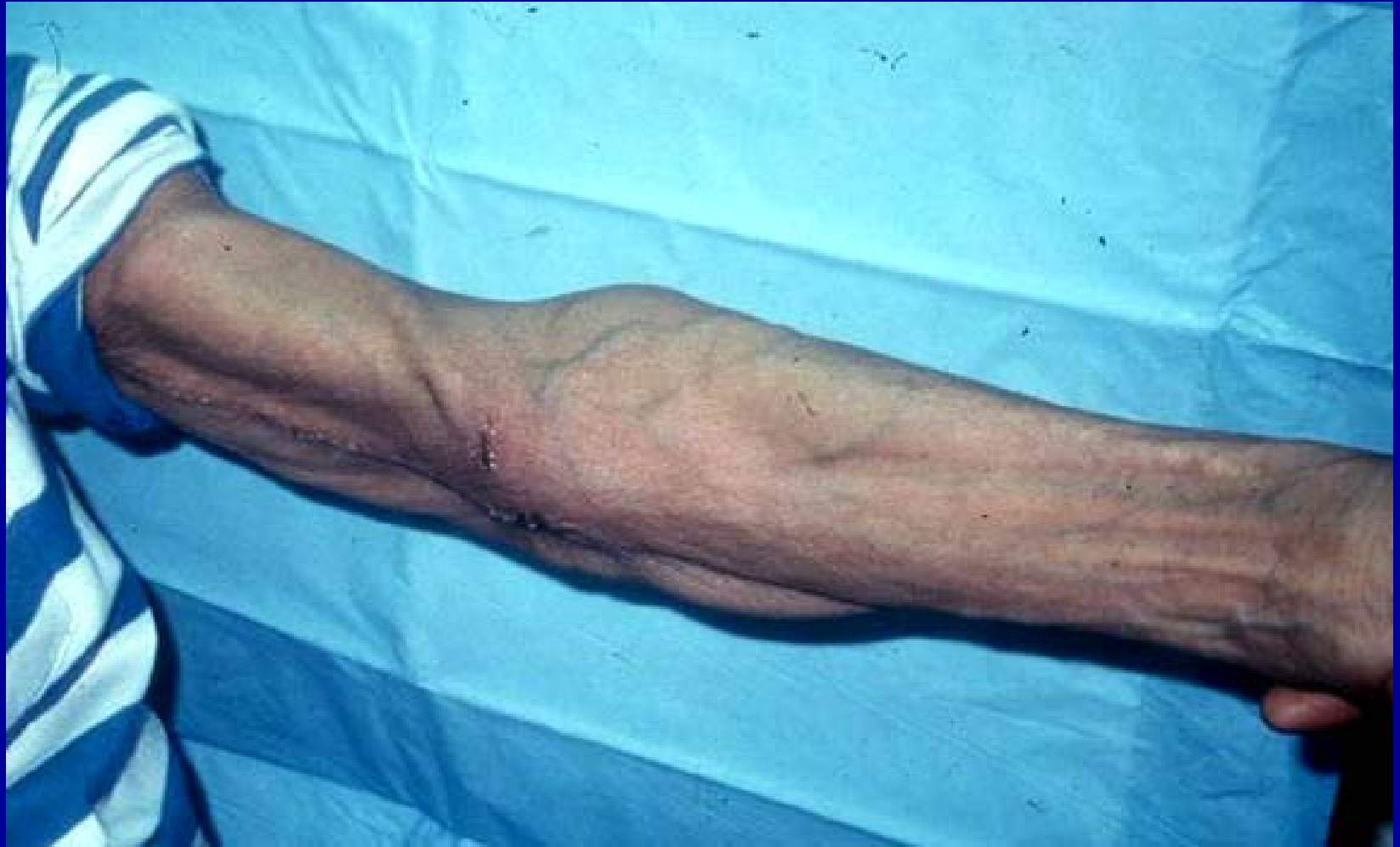# Upper Arm Basilic Vein Transposition

- Basilic vein in upper arm often satisfactory conduit even in the presence of extensive thrombosis of forearm veins
- Deep anatomic position on medial aspect of upper arm makes venipuncture difficult
- Satisfactory access depends on transposition of basilic vein into subcutaneous tunnel
- Can be done in one or two stages

# Basilic Vein Transposition



# Basilic Vein Transposition





# Single vs Two Stage Basilic Vein Transposition

## A Comparison Between Single- and Two-Stage Brachio-basilic Arterio-venous Fistulas

Tyler S. Reynolds, MD, Mohamed Zayed, MD, Karen M. Kim, MD, Jason T. Lee, MD, Brandon Ishaque, Ramanath B. Dukupati, MD, Amy H. Kaji, MD, and Christian deVirgilio, MD, General Surgery, Harbor-UCLA Medical Center, Torrance, CA, and Palo Alto, CA

**Objectives:** Controversy exists as to whether the brachio-basilic arterio-venous fistula (BBAVF) should be performed in one or two stages. We compare primary failure rates, as well as primary and secondary patency rates, of one- and two-stage BBAVF.

**Methods:** Patients undergoing one- and two-stage BBAVF at two institutions were compared retrospectively with respect to age, sex, body mass index, use of preoperative venous duplex ultrasound, diabetes, hypertension, and causes of end-stage renal disease. Categorical variables were compared using  $\chi^2$  and Fisher exact test. The Wilcoxon rank sum test was used to compare continuous variables. Primary and secondary patency rates were assessed using Kaplan-Meier survival analysis and the Cox proportional hazards model.

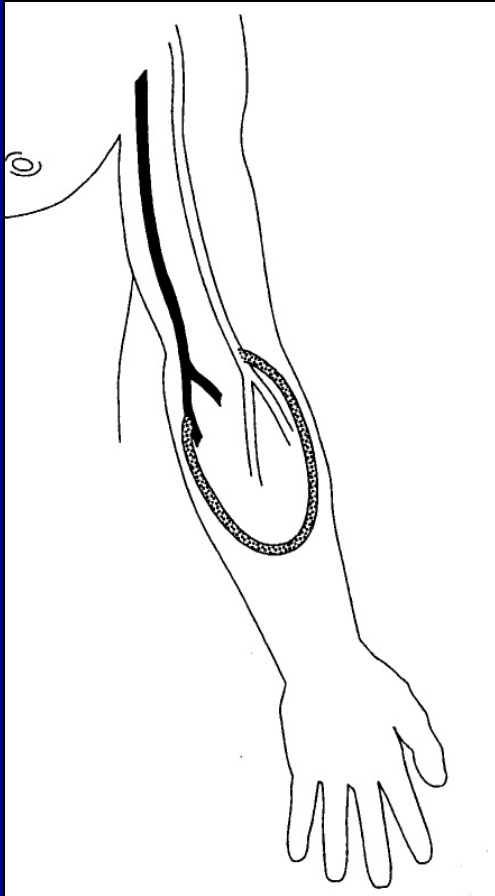
**Results:** The study identified 90 patients (60 one-stage and 30 two-stage). Mean follow-up was 14.2 months, and the mean time interval between the first and second stage was 11.2 weeks. Three patients in each group required procedures to maintain assisted primary patency. Although no significant difference in early failure existed (one-stage, 22.9% vs two-stage, 9.1%,  $P = .2$ ), the two-stage BBAVF showed significantly improved primary patency (hazard ratio, 0.31; 95% CI, 0.09-0.99;  $P = .048$ ) and significantly improved secondary patency (hazard ratio, 0.18; 95% CI, 0.04-0.84;  $P = .03$ ). Mean primary patency for one stage BBAVF was 72.3 weeks and two-stage was 138 weeks (1 SD;  $P = .05$ ). Mean secondary patency was 94 weeks and 139 weeks, respectively (1 SD;  $P = .05$ ). Primary patency at 1 year for one- and two-stage BBAVF was 78% and 84%, respectively ( $P = .05$ ). Functional primary patency at 1 year for one- and two-stage BBAVF was 61% and 88%, respectively ( $P = .05$ ). Complication rates were not statistically different (each greater than  $P = .11$ ).

**Conclusions:** Patency rates appear to be improved with the two-stage BBAVF. There is no difference in the complication rate. Optimal surgical techniques for patients undergoing BBAVF for dialysis are discussed. Longer-lasting hemodialysis access improves patient outcome and decreases morbidity associated with dialysis.

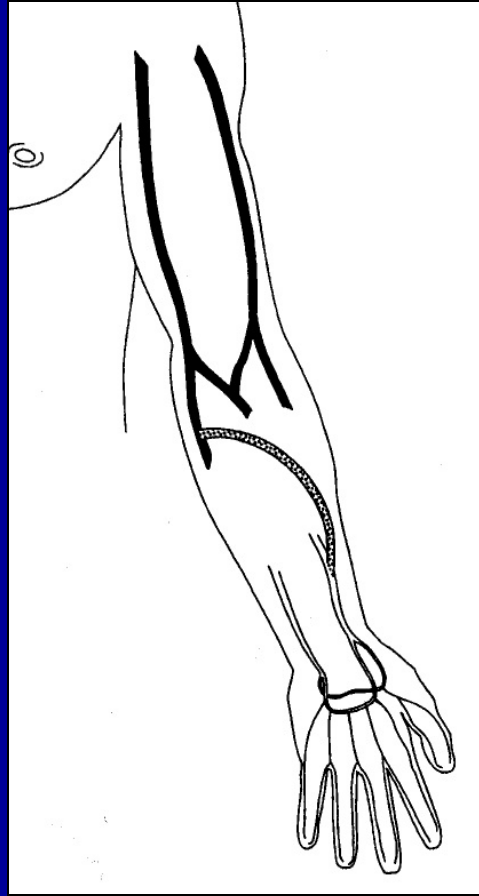
Patency rates appear to be improved with the two-stage brachio-basilic AVF

Western  
Vascular  
Society  
2010

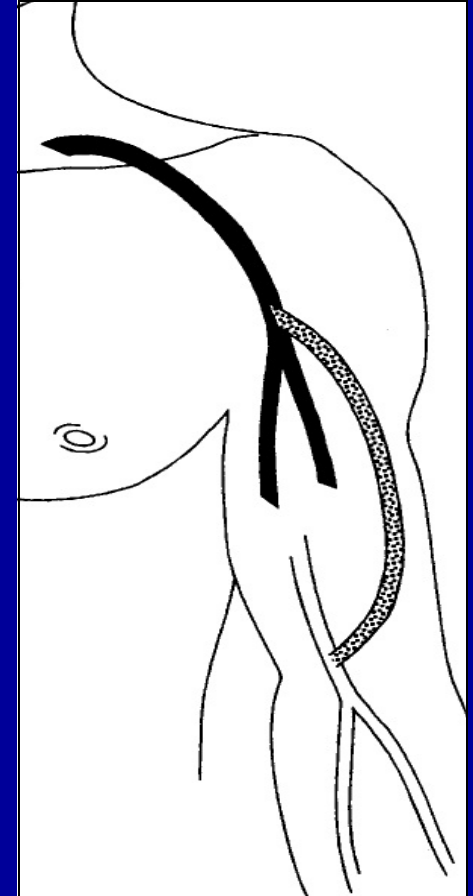
# Configuration of Upper Extremity AV Grafts



**Loop Forearm**

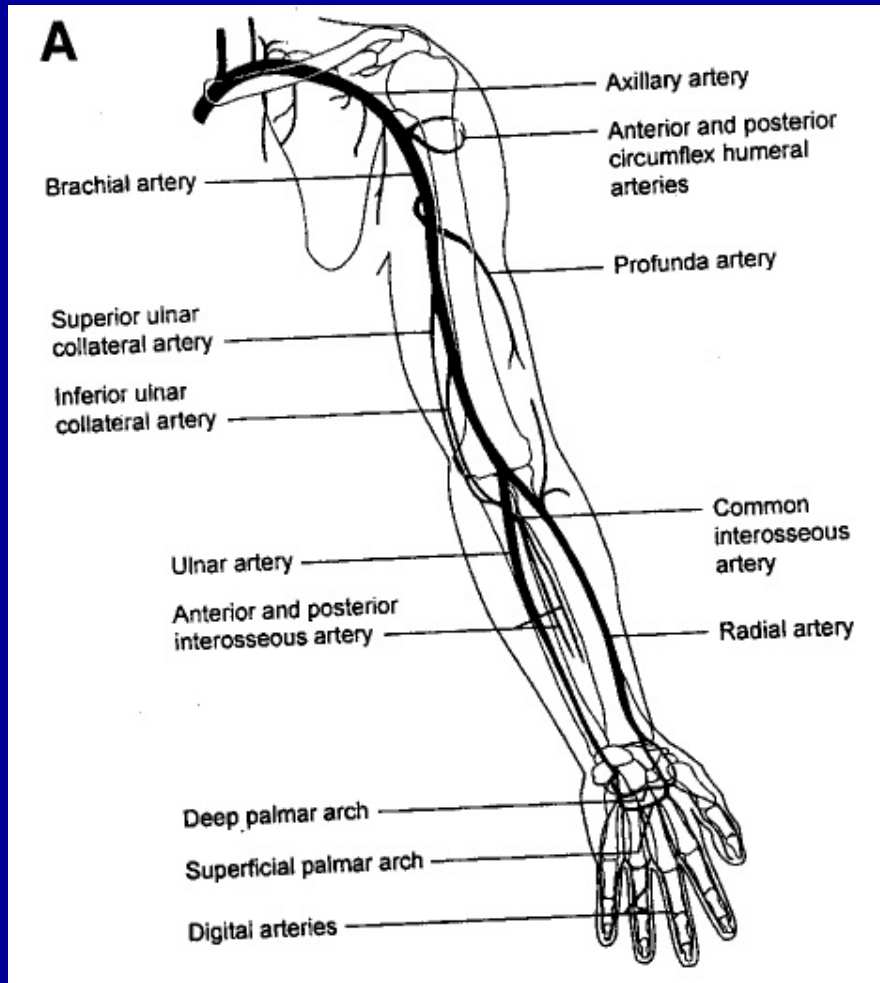


**Straight Forearm**

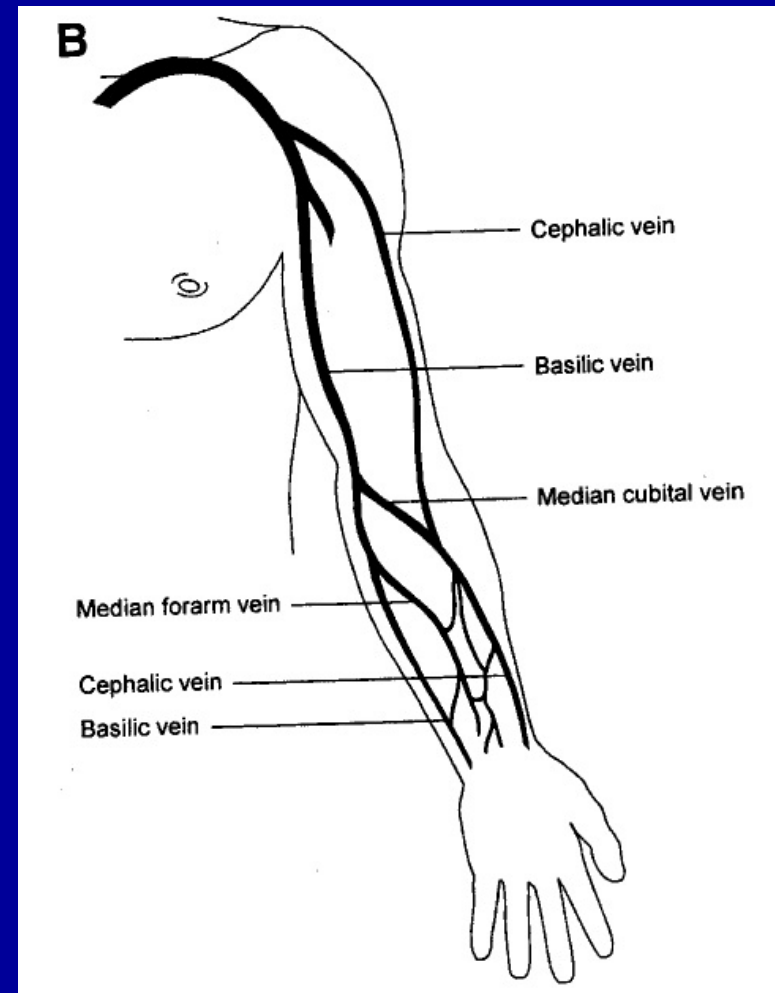


**Brachioaxillary**

# Normal Upper Extremity Anatomy



**Arterial Anatomy**



**Venous Anatomy**

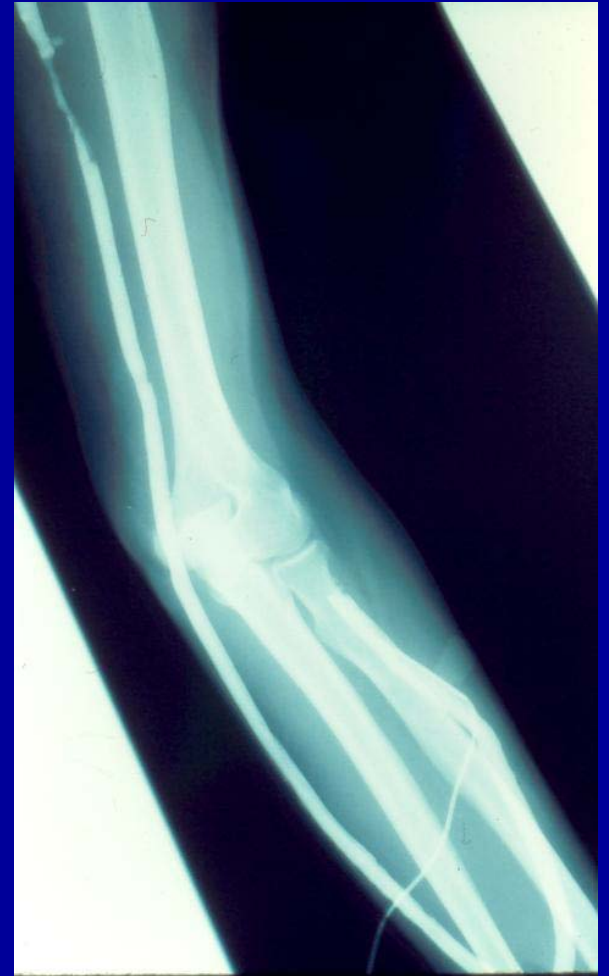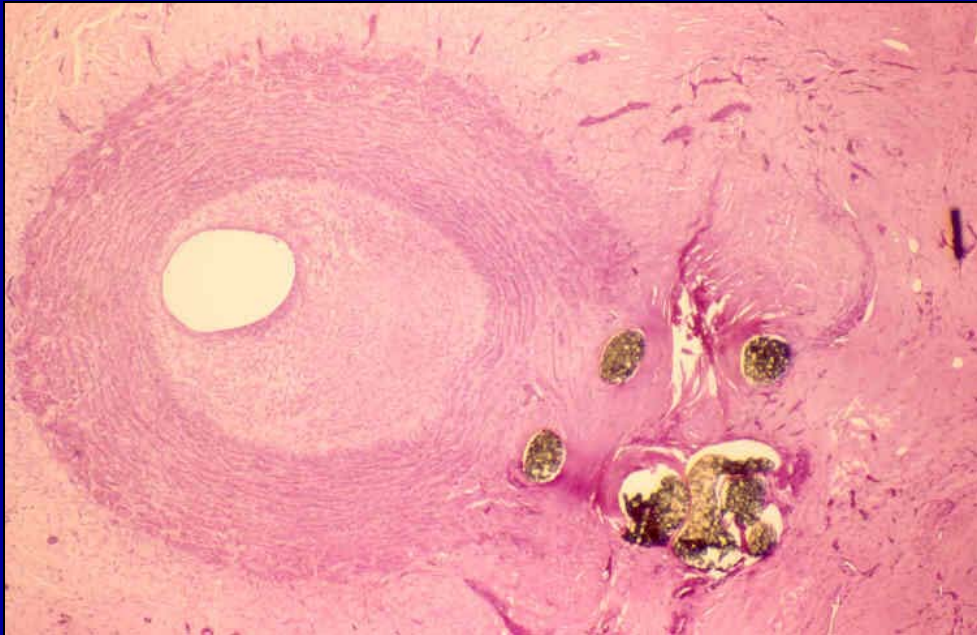
# Alternative Graft Materials for Hemodialysis Access

- (Saphenous vein)
- (Bovine heterograft)
- (Umbilical vein)
- (Dacron)
- PTFE
- Polyurethane (Vectra<sup>R</sup>)
- Bovine mesenteric vein (ProCol<sup>R</sup>)
- Cryopreserved femoral vein allograft (CryoVein<sup>R</sup>)
- Bovine carotid artery (Artegraft)

# What is the best graft material for hemodialysis access?

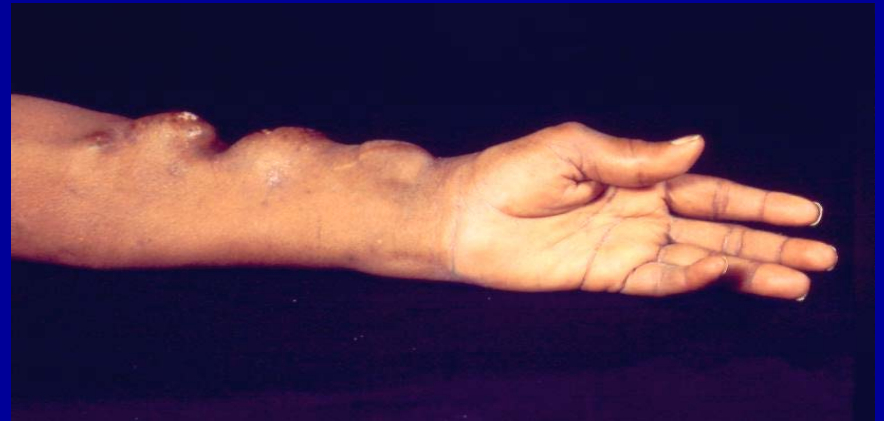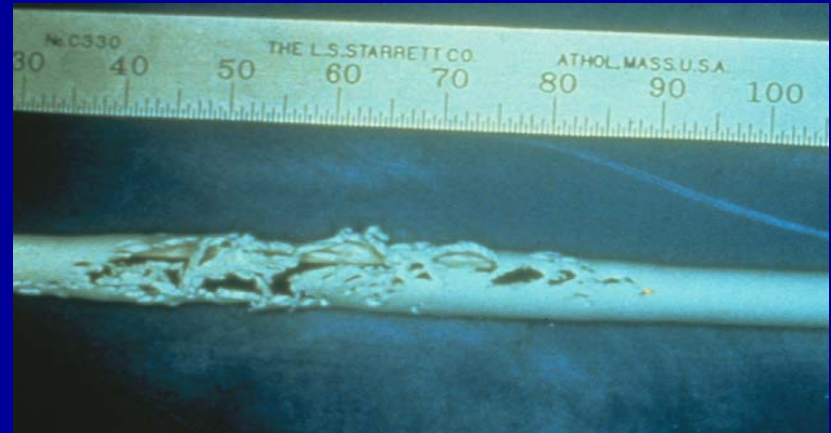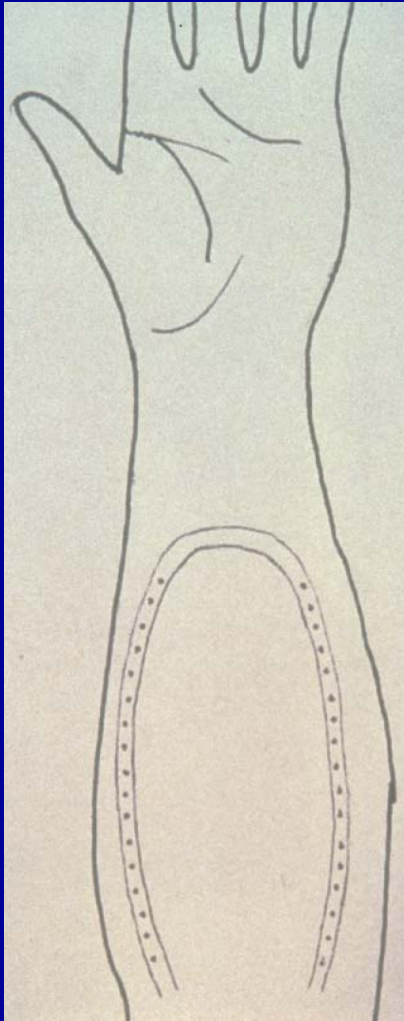
Almost 40 years after the introduction of PTFE graft material for dialysis access, **no** alternative graft material has been **proven** to be better.

# Neointimal Hyperplasia



# “One-site-itis”

Destruction of PTFE graft material by repeated puncture at one site.



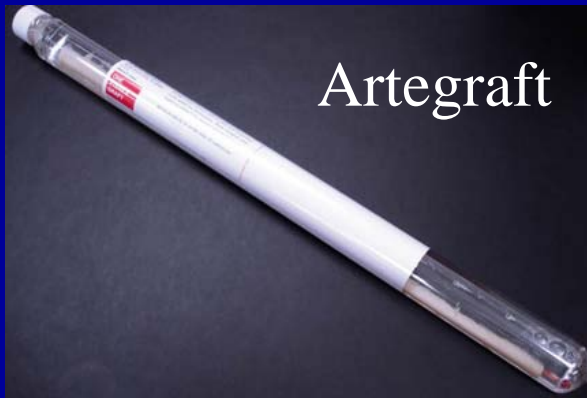# Goals of modifying graft materials

- **Improve 1<sup>o</sup> and 2<sup>o</sup> patency**
- **Reduce complications**
  - **Pseudoaneurysms**
  - **Infection**
  - **Vascular steal**
- **Facilitate early access**
- **Reduce bleeding after puncture**
- **Facilitate thrombectomy**

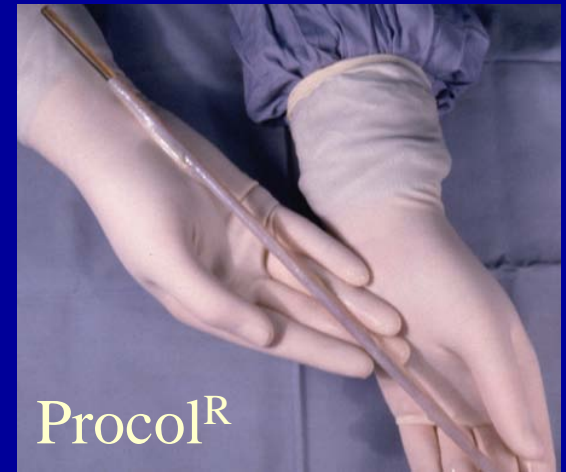
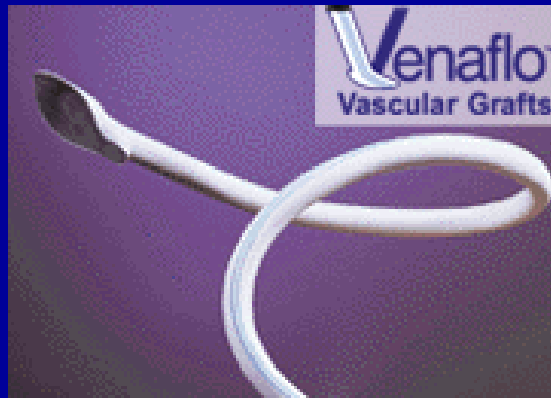
# **PTFE Graft Modifications for Improved Hemodialysis Access Patency**

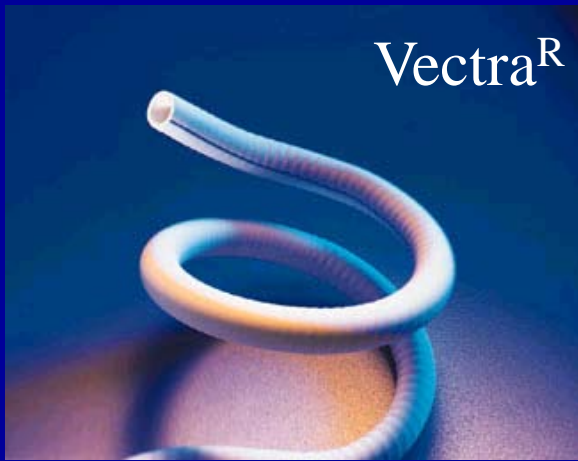- **Rings**
- **Outer wrap**
- **Taper**
- **Wall thickness**
- **Venous cuff**
- **Carbon coating**
- **Tunneling sheaths**
- **Pore size**
- **Stretch**
- **Swirl**



Artegraft



Procol<sup>R</sup>

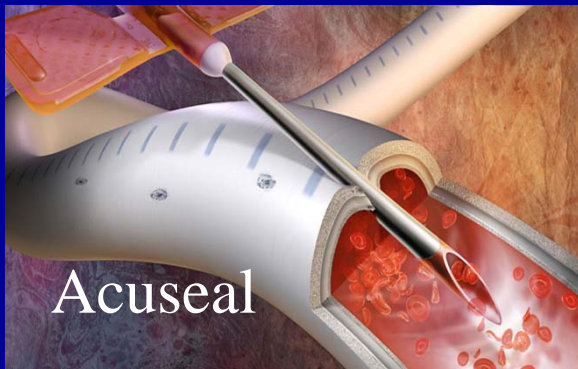


Vectra<sup>R</sup>

**Alternative  
Graft  
Materials  
For  
Hemodialysis  
Access**



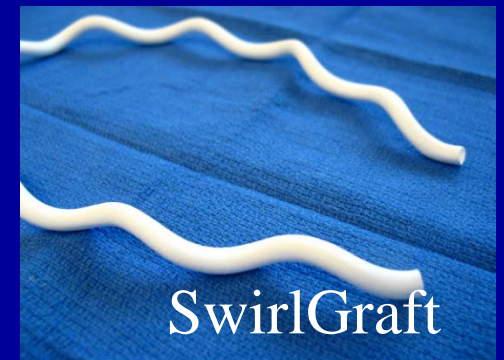
Slider<sup>TM</sup>



Acuseal



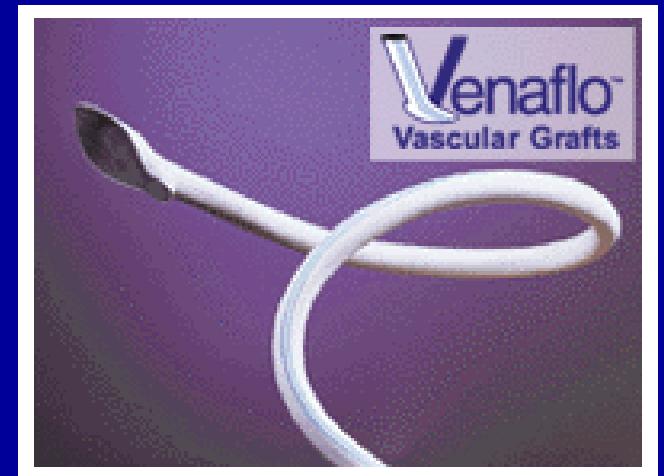
HeRO



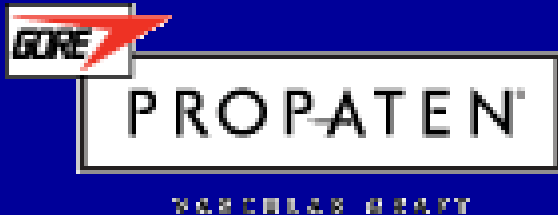SwirlGraft

# Venaflo™ Graft

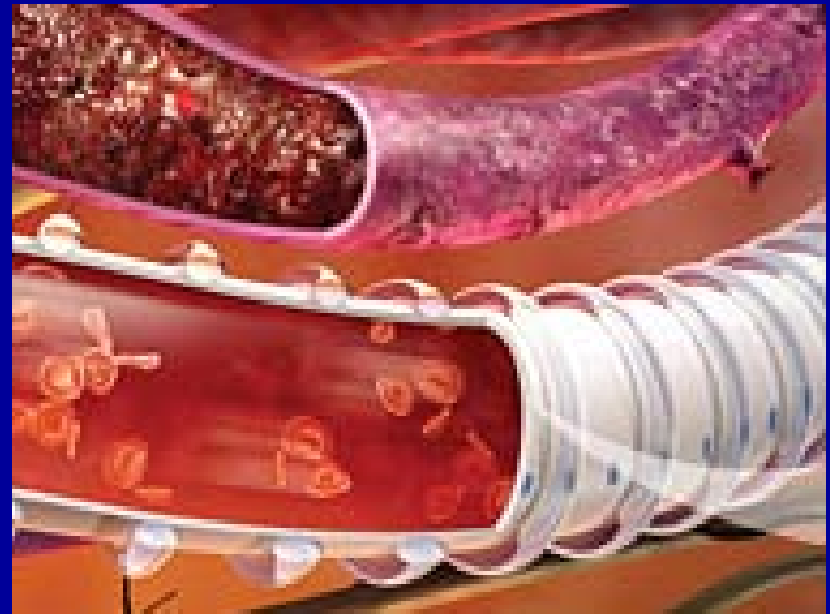
- Hooded AVG (Designed to provide stable, organized laminar high flow into veins to prevent intimal hyperplasia)
- One-piece construction with cuff designed to be trimmed to match recipient vein size



# Gore Propaten Graft



- Heparin bonded
- Improved patency?



# Vectra<sup>R</sup> Vascular Access Graft

- Multilayered, self-sealing polyurethane vascular access graft (PVAG)
- Technical complications (eg-kinking) can be avoided by using a double sheathed implant technique.
- *Early access is possible without sacrificing long-term performance.*
- *Time to hemostasis after cannulation significantly reduced*



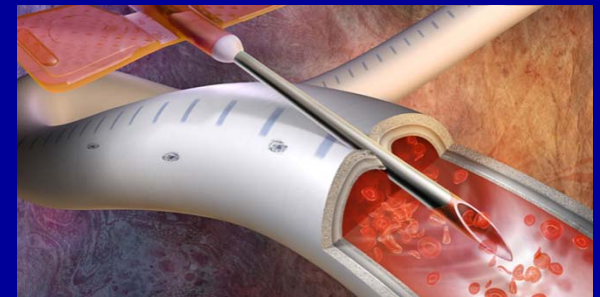
# Atrium Flixene™ Vascular Graft

- “next generation” composite graft
- proprietary biomaterial film lamination process
- improved
  - strength
  - kink resistance
  - surgical handling
  - resistance to weeping



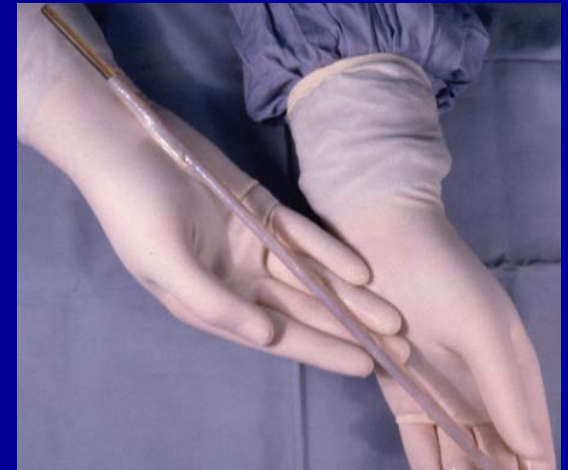# GORE<sup>R</sup> Acuseal Graft

- low-bleed, tri-layer vascular graft
- elastomeric middle membrane between inner and outer layers of expanded polytetrafluoroethylene (ePTFE).
- hinders suture line and cannulation needle bleeding.
- may reduce the risk of seroma and pseudoaneurysm formation



# ProCol<sup>R</sup> Vascular Bioprosthesis

- Bioartificial vascular conduit derived from bovine mesenteric vein.
- ProCol<sup>R</sup> safe alternative to PTFE for hemodialysis access with superior patency in high-risk patients prone to access-related thrombosis.





**Artegraft<sup>®</sup> Bovine Carotid Artery Graft<sup>™</sup>**

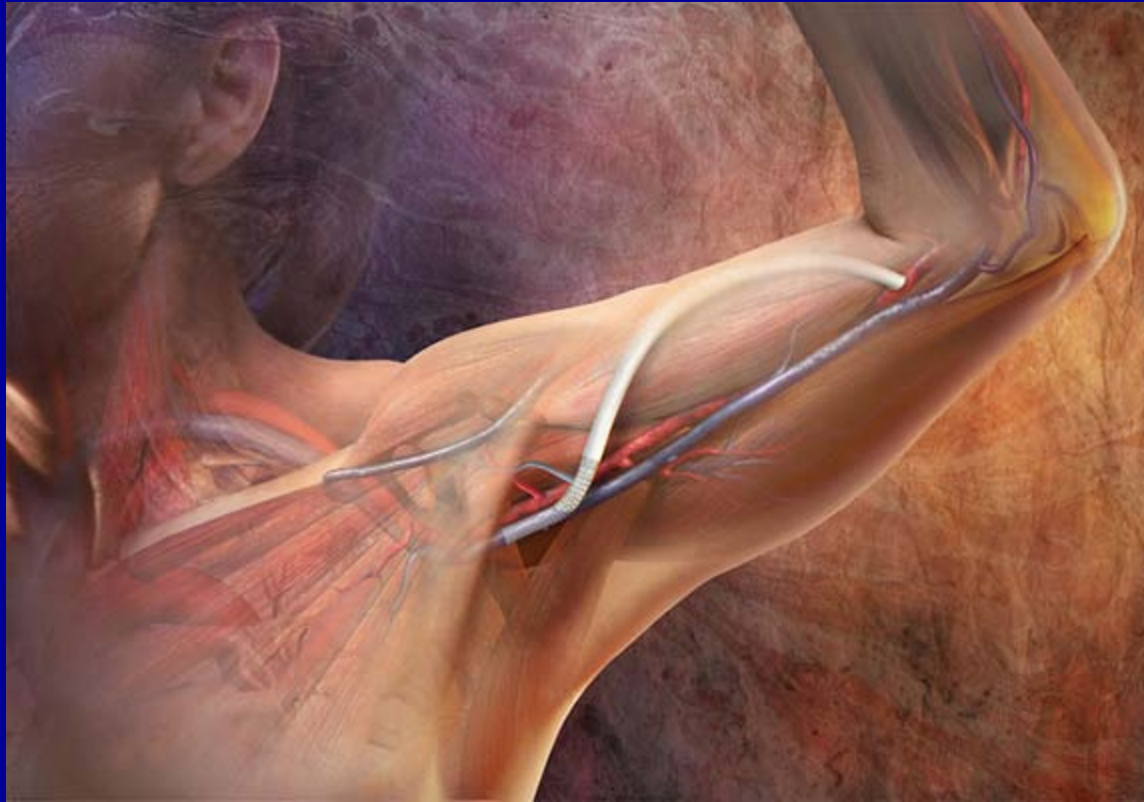

**A Prospective, Randomized Comparison  
of Bovine Carotid Artery and Expanded  
Polytetrafluoroethylene for Permanent  
Hemodialysis Vascular Access**

Journal of Vascular Surgery, Volume 53,  
Issue 6, Pages 1640-1648, June 2011.

**Conclusion**

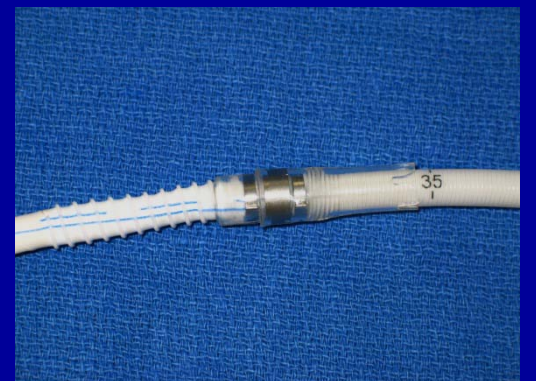The BCA graft is an excellent option for patients on hemodialysis that are not suitable for native arteriovenous fistulas, as these grafts required fewer interventions than the ePTFE grafts to maintain patency.



The **GORE® Hybrid Vascular Graft** is an expanded Polytetrafluoroethylene (ePTFE) vascular prosthesis that provides a streamlined solution for challenging dialysis access.

# HeRO Device

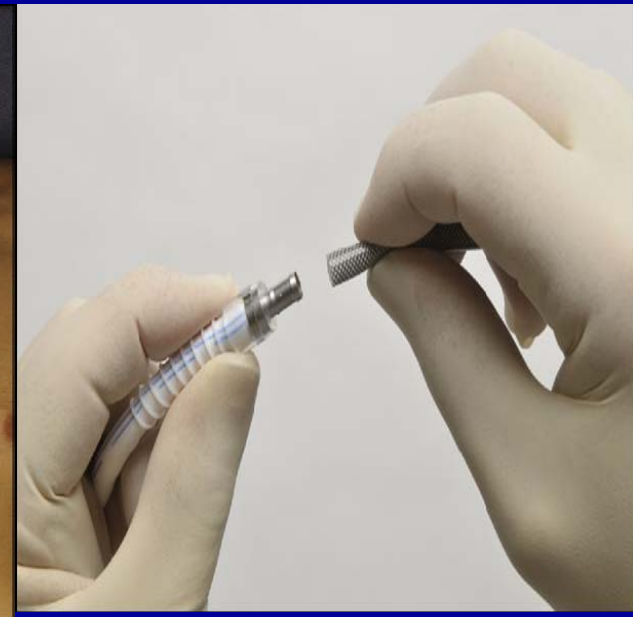
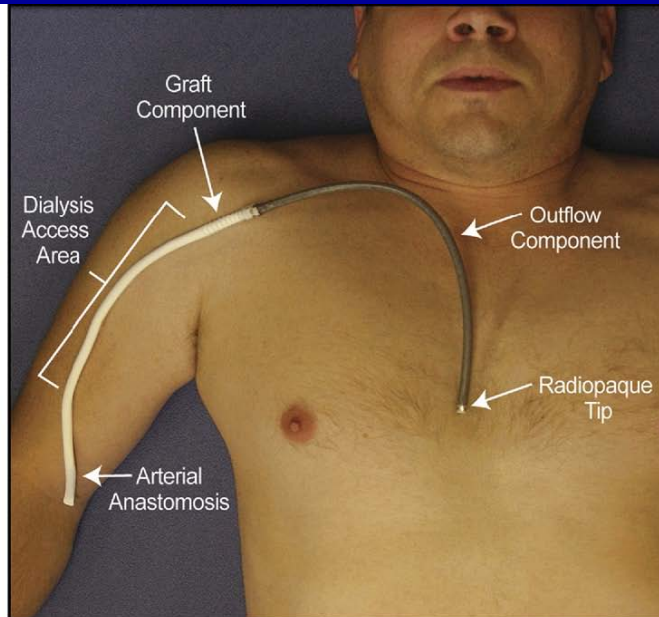
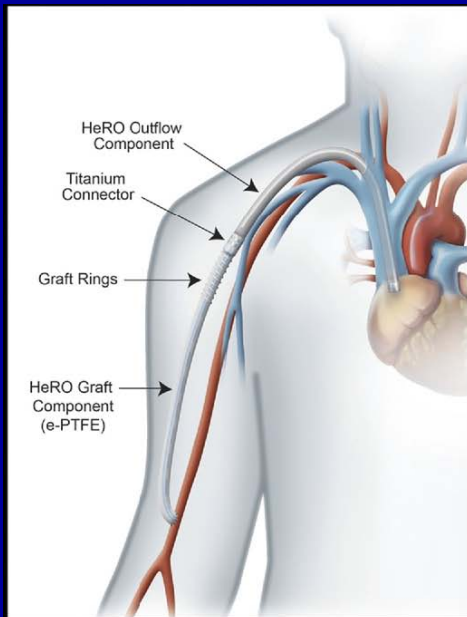
- **Avoids venous anastomosis by transitioning ePTFE graft with traditional arterial anastomosis into single-lumen silicone catheter inserted via internal jugular vein into the SVC or RA**
- **Conduit fully implanted and accessed in typical percutaneous fashion**
- **Catheter portion secures venous outflow only and avoids fibrin sheath-mediated inflow restriction**

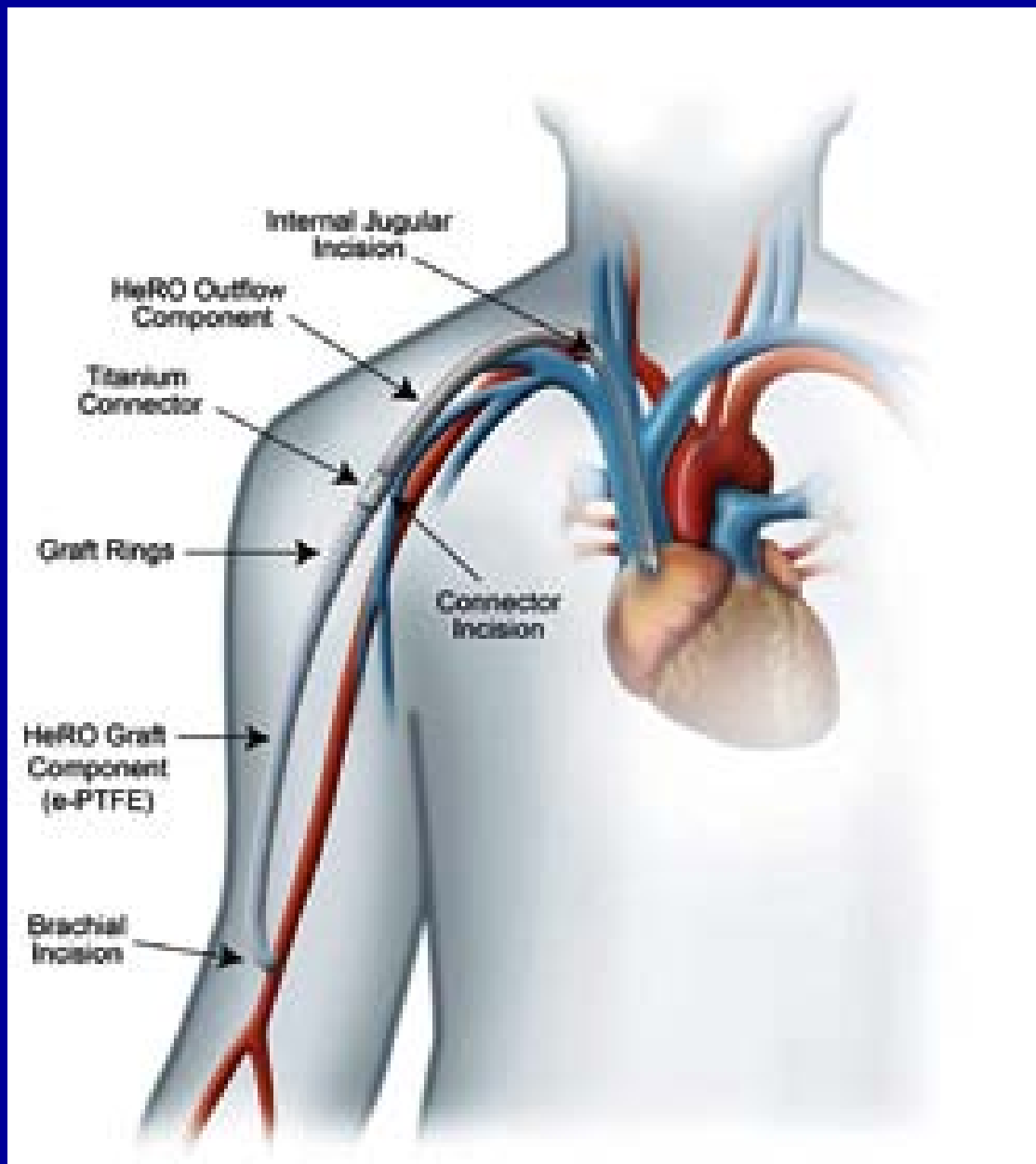


# Initial experience and outcome of a new hemodialysis access device for catheter-dependent patients

Howard E. Katzman, MD,<sup>a</sup> Robert B. McLafferty, MD,<sup>b</sup> John R. Ross, MD,<sup>c</sup> Marc H. Glickman, MD,<sup>d</sup> Eric K. Peden, MD,<sup>e</sup> and Jeffery H. Lawson, MD, PhD,<sup>f</sup> *Miami, Fla; Springfield, Ill; Bamberg, SC; Norfolk, Va; Houston, Tex; and Durham, NC*

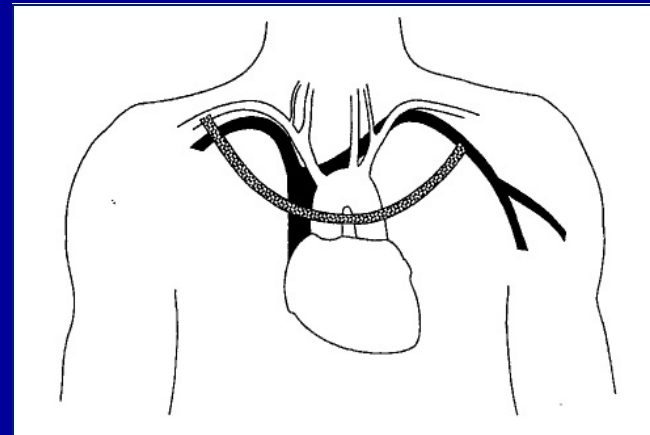
(J Vasc Surg 2009;50:600-7.)



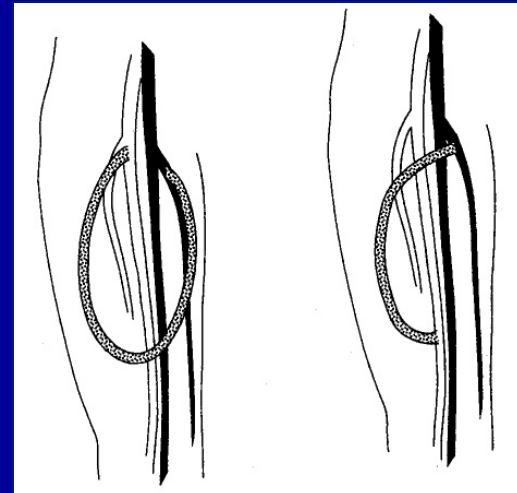


# Alternative options for AV access

Chest wall



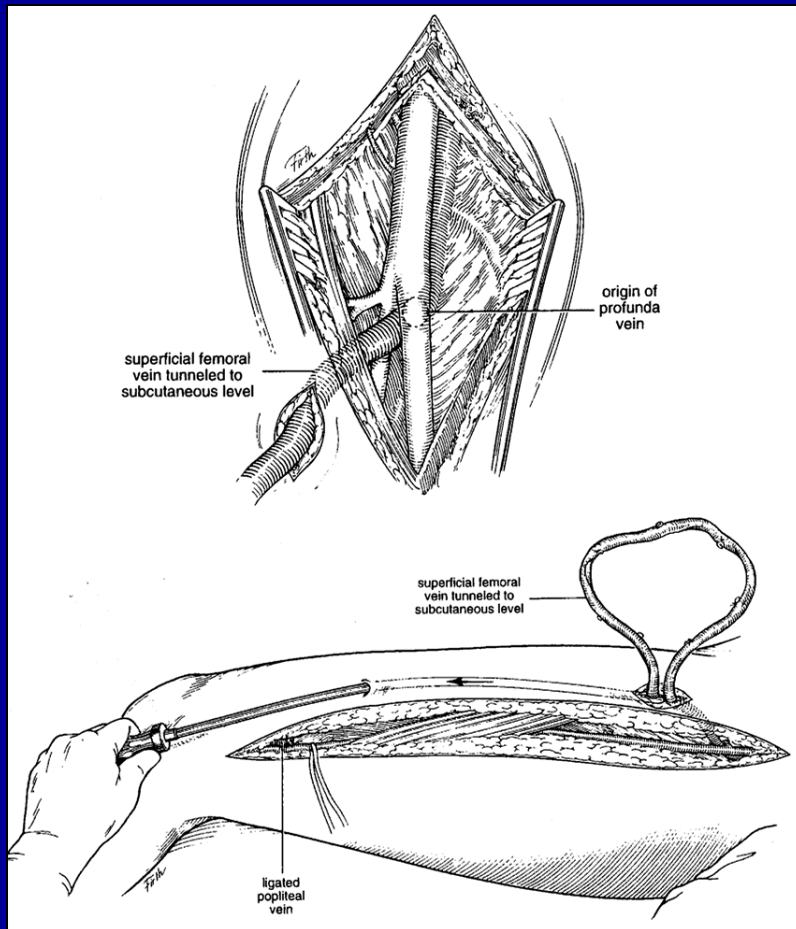
Lower extremity



# Lower Extremity AV Grafts

- Taylor et al. (Am Surg 1996;62:188-91)
  - 45 leg AV grafts in 39 patients
  - Primary patency 47% at 24 months
  - Infection 18%, leg ischemia 16%
  - Marker for late mortality
- Vogel et al. (South Med J 2000;93:593-5)
  - 134 (16% of all AV grafts) patients
  - 62% 12 month graft survival
  - Mean graft patency 13.8 months
  - Infection 46%, thrombosis within 1 month 28%

# Arteriovenous fistula with transposed superficial femoral vein



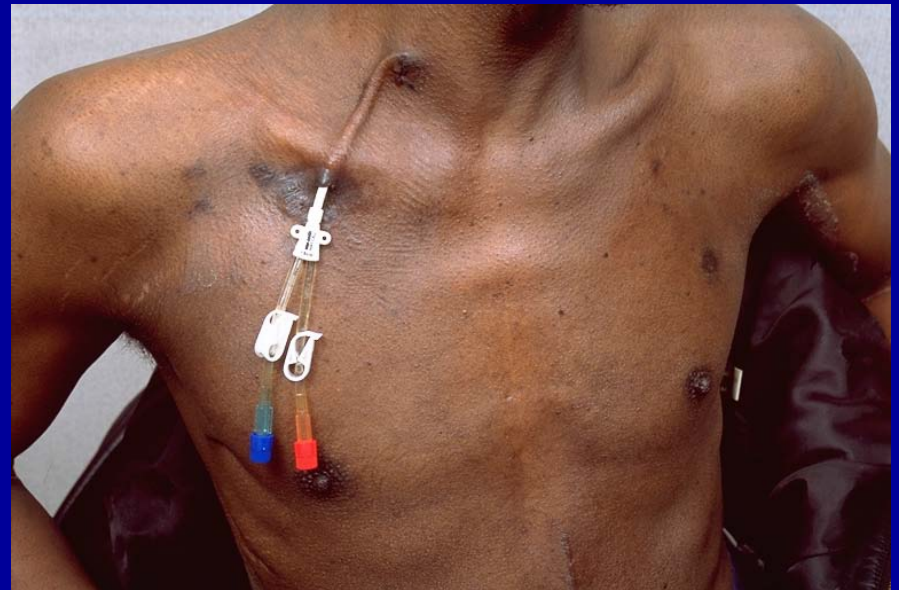- Gradman et al., JVS 33:968,2001
- 25 patients
- Twelve month 1<sup>o</sup> patency 73%
- Twelve month 2<sup>o</sup> patency 86%
- Thrombosis, fistula infection and venous hypertension uncommon
- Wound complications and steal syndrome problematic



# Disadvantages of Tunneled Cuffed Catheters

---

- **Lower blood flow rates**
- **High morbidity due to thrombosis and infection**
- **Discomfort and cosmetic disadvantage of an external appliance**
- **Shorter expected use-life than other access types**



# Fistula Maturation

**Table 1 Objective Criteria for Fistula Maturation**

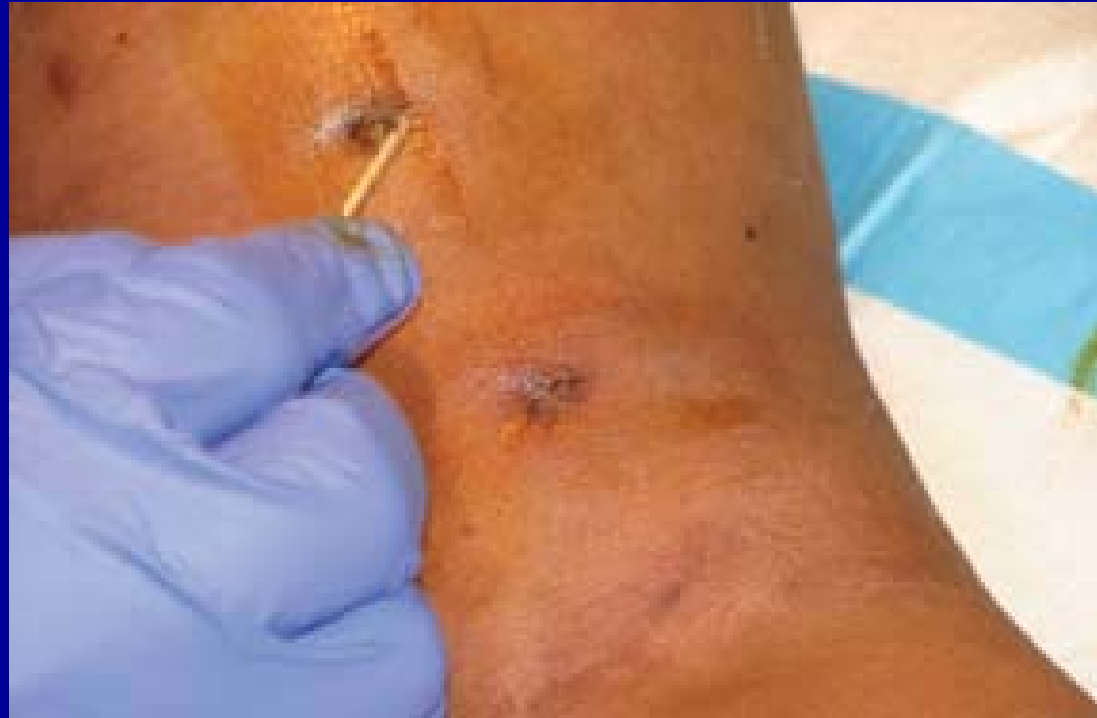---

Fistula flow	>600 mL/min
Needle stick segment (conduit)	>10 cm long or two 4-cm segments each >6 mm in diameter <5 mm deep from skin surface

---

**Innovative Surgical Approaches to Maximize Arteriovenous Fistula Creation**  
Shenoy, Seminars in Vascular Surgery 2007

# Buttonhole Cannulation



# Effect of Clopidogrel on Early Failure of Arteriovenous Fistulas for Hemodialysis

- Dialysis Access Consortium Study Group, Dember et al, JAMA, 2008
- Clopidogrel reduces frequency of early thrombosis of new AVF but does not increase proportion of fistulas that become suitable for dialysis (*nonmaturation*)
- **Failure to attain suitability for dialysis (877 patients)**
  - Clopidogrel group (61.8%)
  - Placebo group (59.5%)

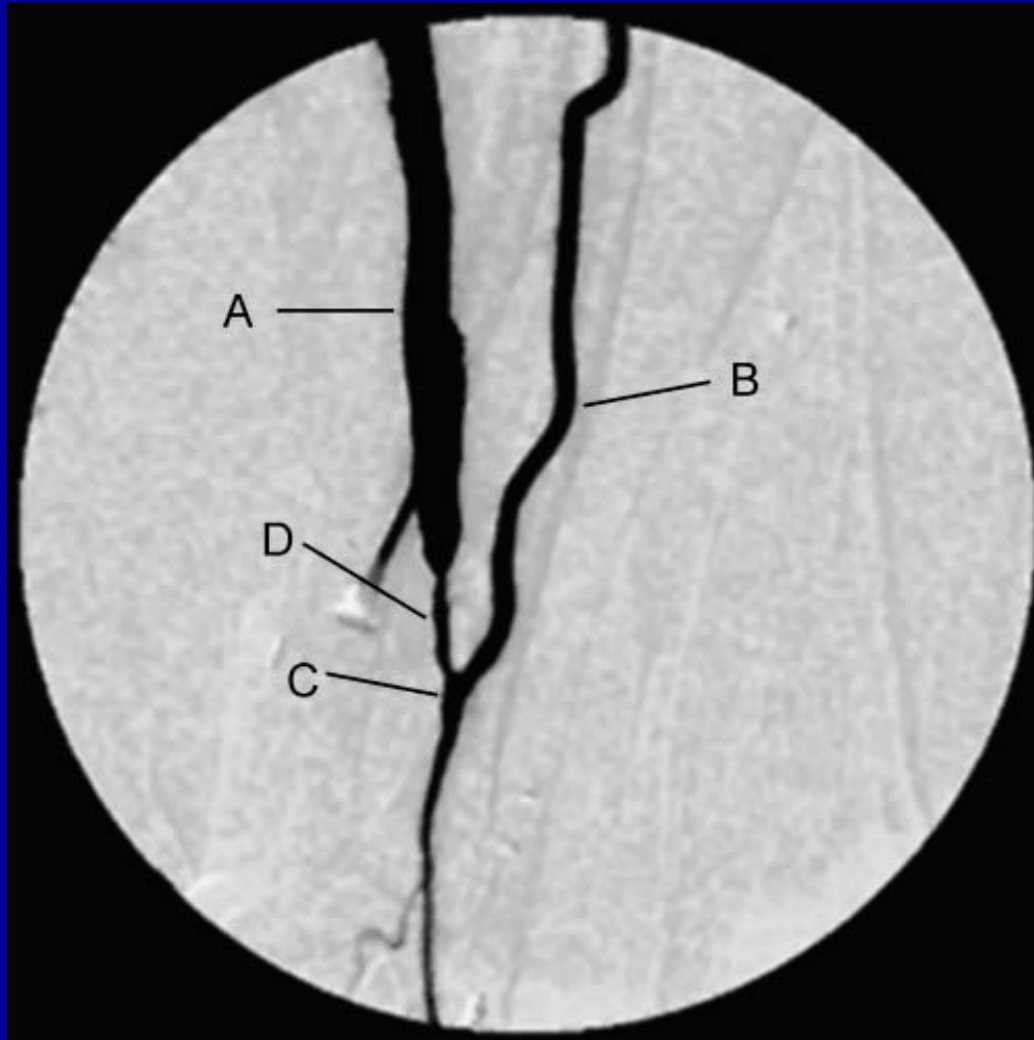
# Options to deal with poor fistula maturation

- Fewer fistulas, more grafts (vein size?)
- Better patient selection (age?)
- Aggressive assessment of immature or failing fistulas at 4-6 weeks with 2<sup>o</sup> intervention
  - Surgical revision
  - Endovascular therapy
  - Balloon maturation

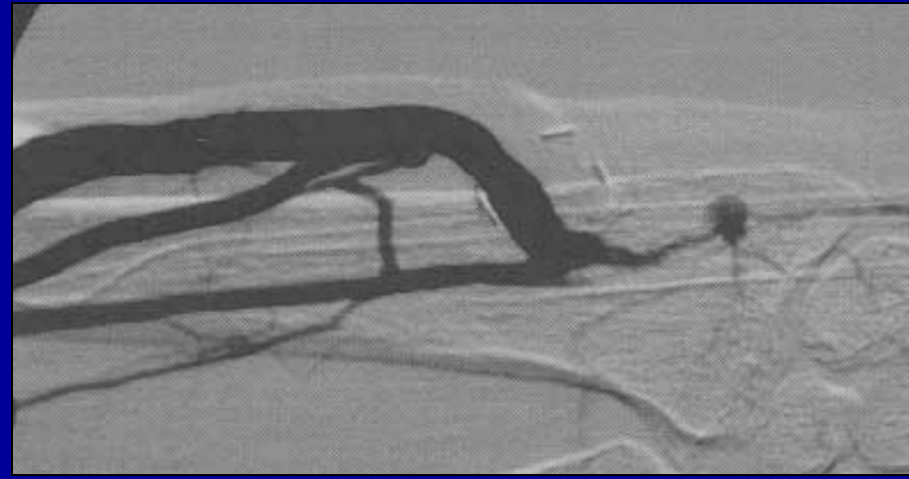
# Interventions to Salvage Fistulas With Early Failure

- Balloon angioplasty of lesions
- Accessory vein obliteration
- One state vs. sequential dilatation
- Surgical revision

# Typical Juxta-anastomotic Venous Stenosis



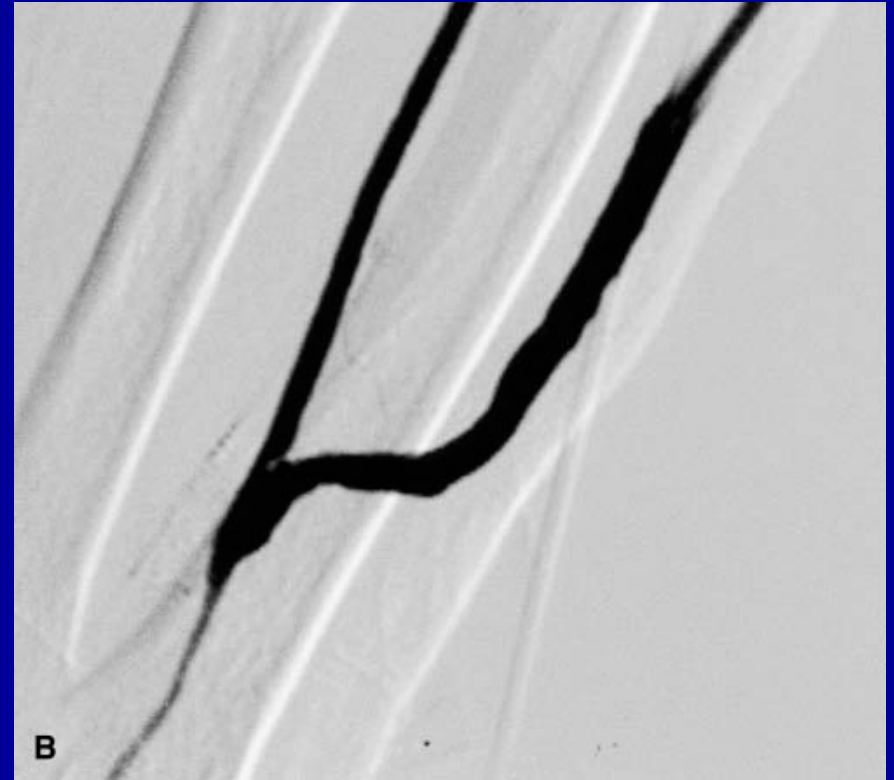
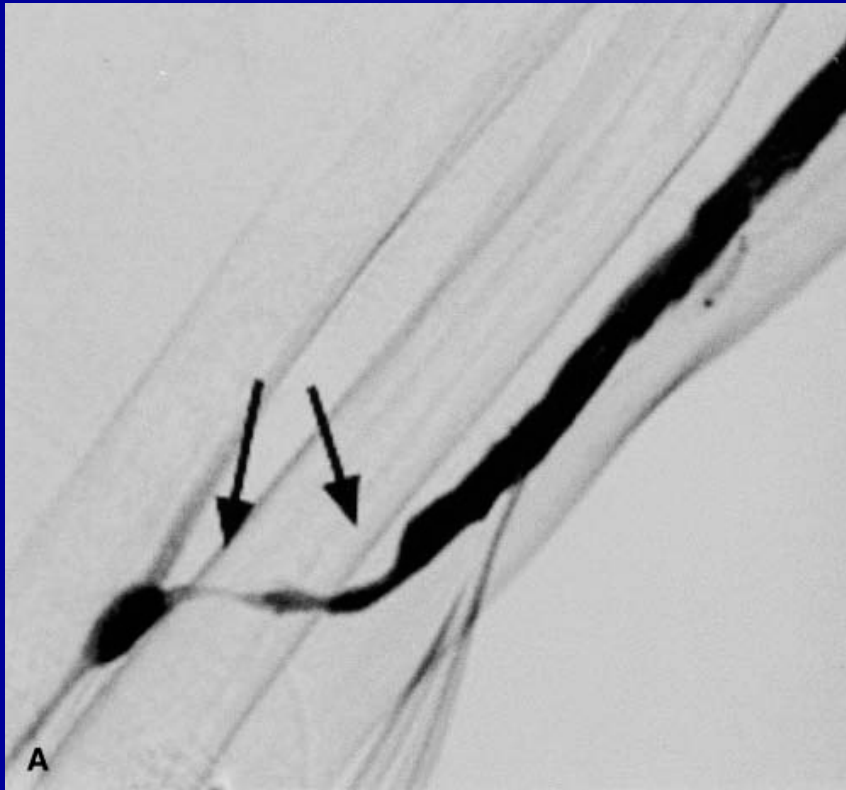# **Surgical Revision of AVF Juxta-anastomotic Stenosis**



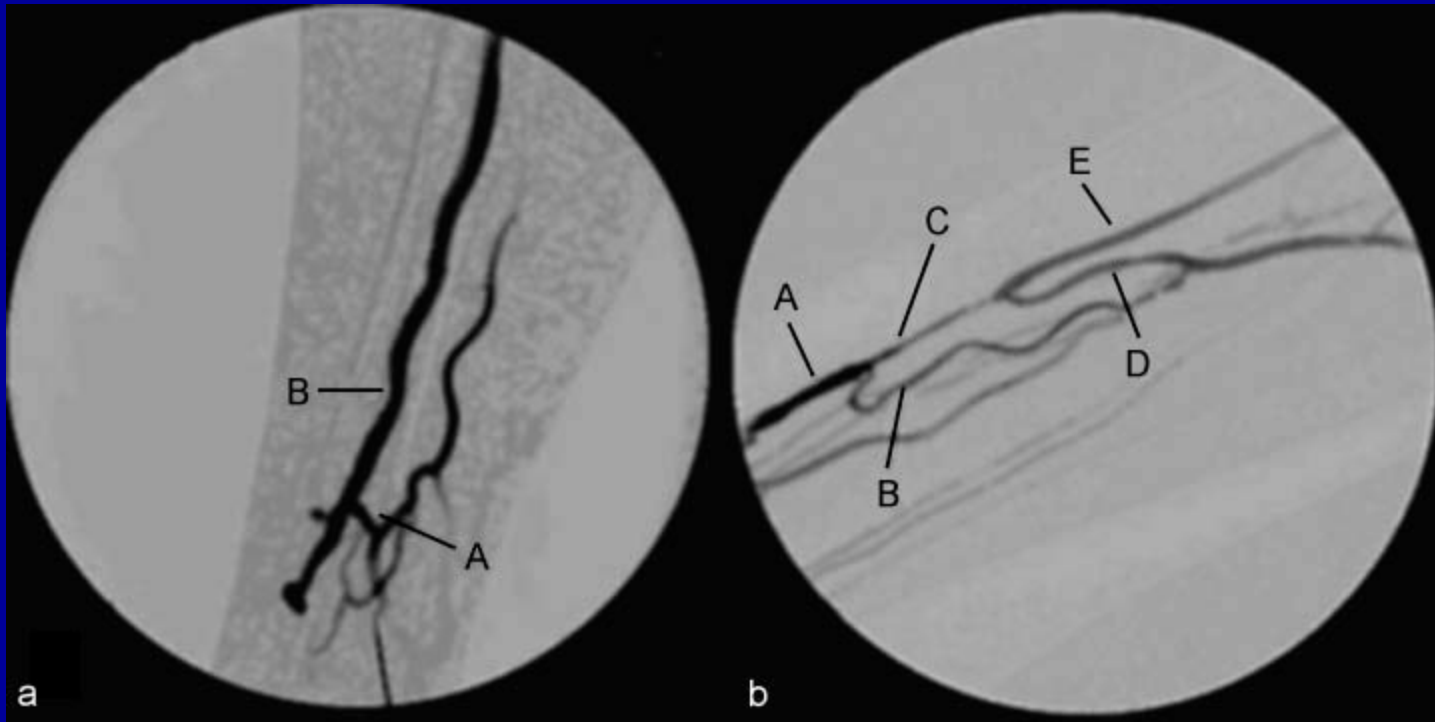
**Berman, et al, J Vasc Surgery, 2001**



# Angioplasty of AVF Juxta-anastomotic Stenosis



Beathard, Semin Dial, 2005




Beathard, Gerald A.

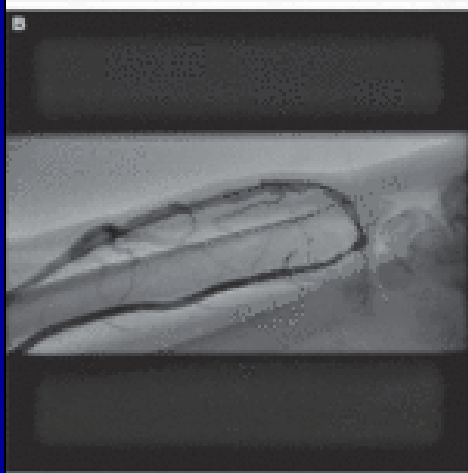
An Algorithm for the Physical Examination of Early Fistula Failure.

*Seminars in Dialysis* **18** (4), 331-335.

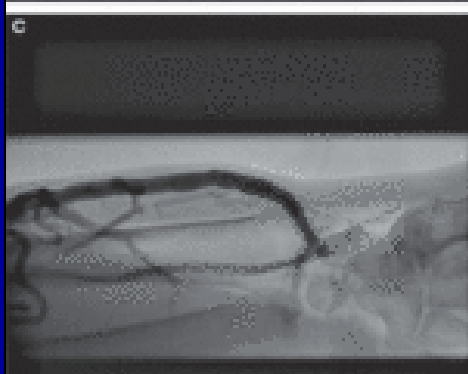
Fig. 3. (a) Accessory vein: (A) accessory vein, (B) fistula. (b) Collateral vein: (A) fistula, (B) collateral (below stenosis), (C) stenosis, (D) accessory vein (above stenosis), (E) upper fistula.



**(A) Poorly maturing wrist fistula - catheter placed retrograde into the radial artery via the fistula.**



**(B) Fistula inflow stenosis visualized.**



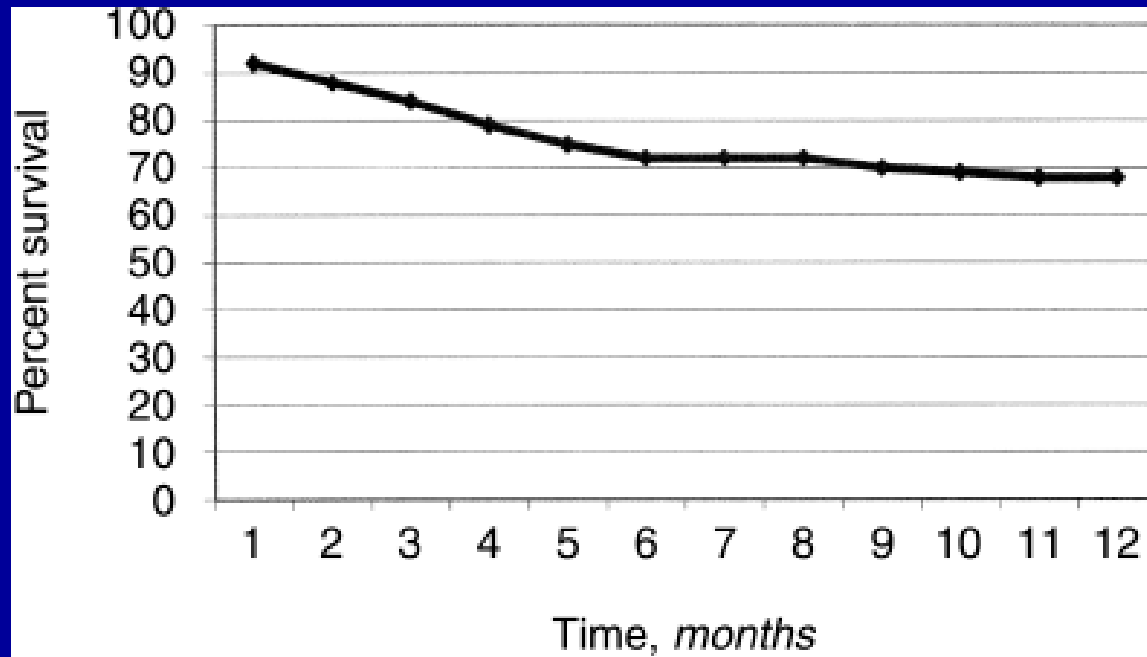
**(C) Improved fistula flow following angioplasty of radial artery**

# **Aggressive Treatment of Early Fistula Failure**

*Beathard, et al., Kidney Int (2003)*

- **100 patients with early failure**
- **Causes of failure**
  - **Venous stenosis (78%)**
  - **Juxtaanastomotic stenosis (43%)**
  - **Presence of accessory veins (24%)**
  - **Arterial stenosis (38%)**
- **Angioplasty (72 patients), obliteration of accessory veins (43 patients)**
- **Staged sequential angioplasty (initially 4 mm balloon)**

# Primary patency of patients with early fistula failure after therapy



Gerald A Beathard, et al, *Kidney Int* (2003)

From the Society for Clinical Vascular Surgery

## Primary balloon angioplasty plus balloon angioplasty maturation to upgrade small-caliber veins (<3 mm) for arteriovenous fistulas

Lorena P. De Marco Garcia, MD, Luis R. Davila-Santini, MD, Qin Feng, MD, Julio Calderin, MD, Kambhampaty V. Krishnasastry, MD, and Thomas F. Panetta, MD, *Manhasset, NY*

(*J Vasc Surg* 2010;52:139-44.)

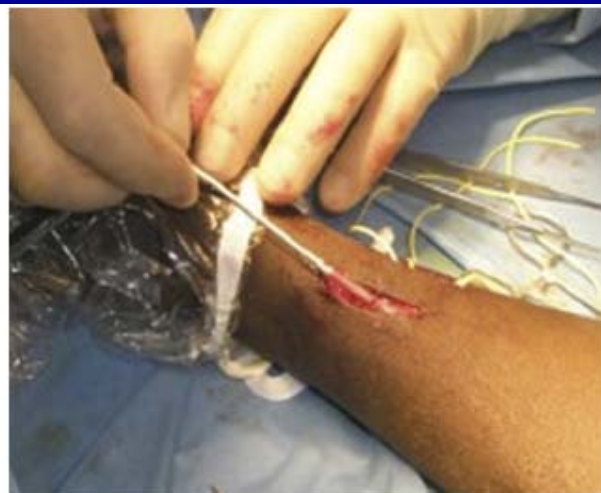

Fig 1. Balloon placement over 0.35-inch angled wire.

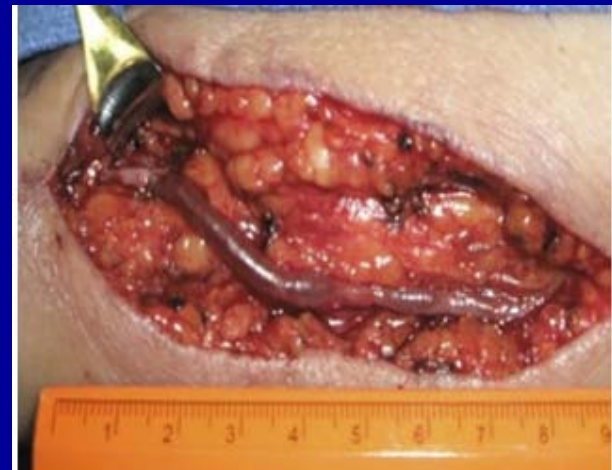
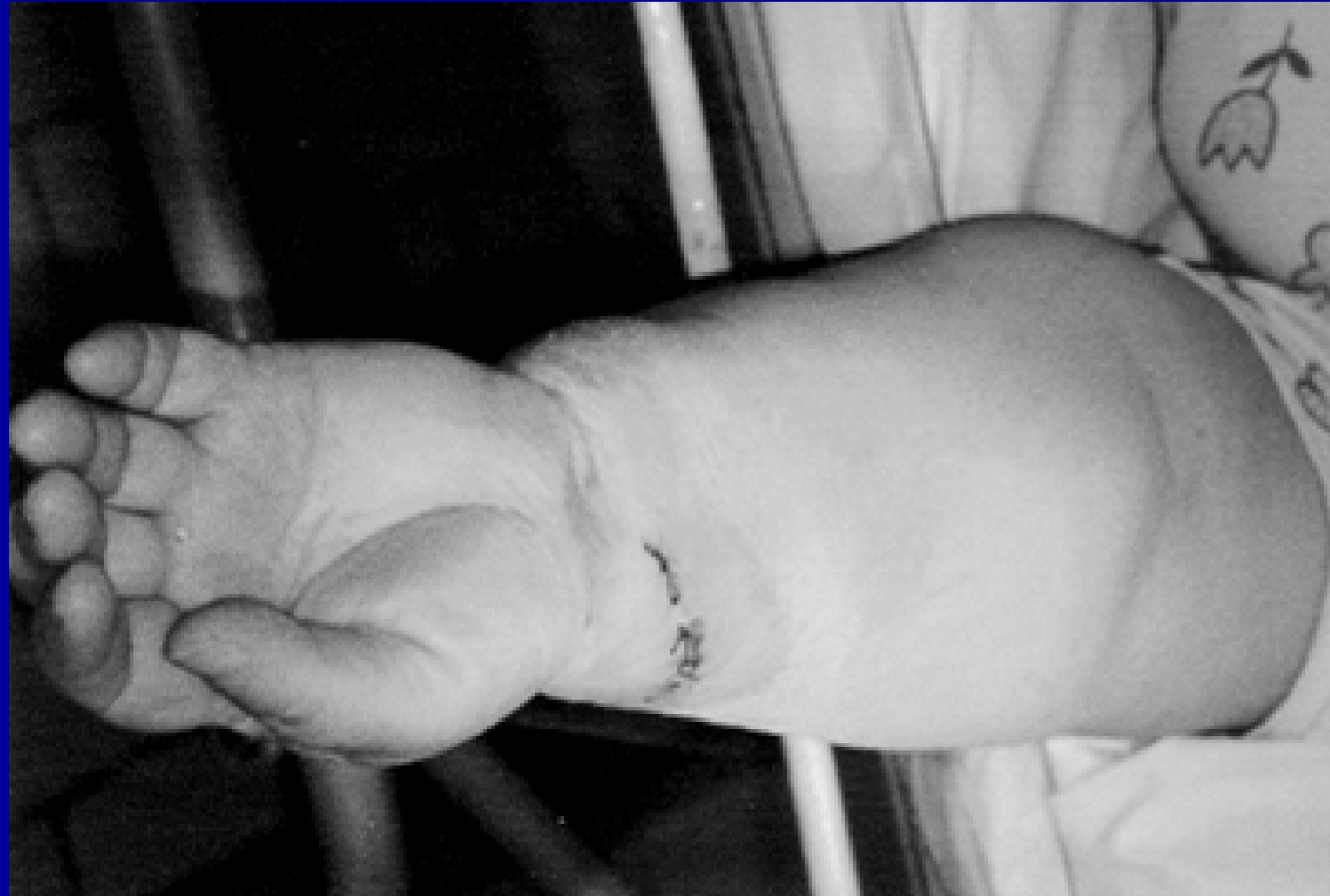
Fig 2. Vein after anastomosis.

# Superficialization of AV Fistula



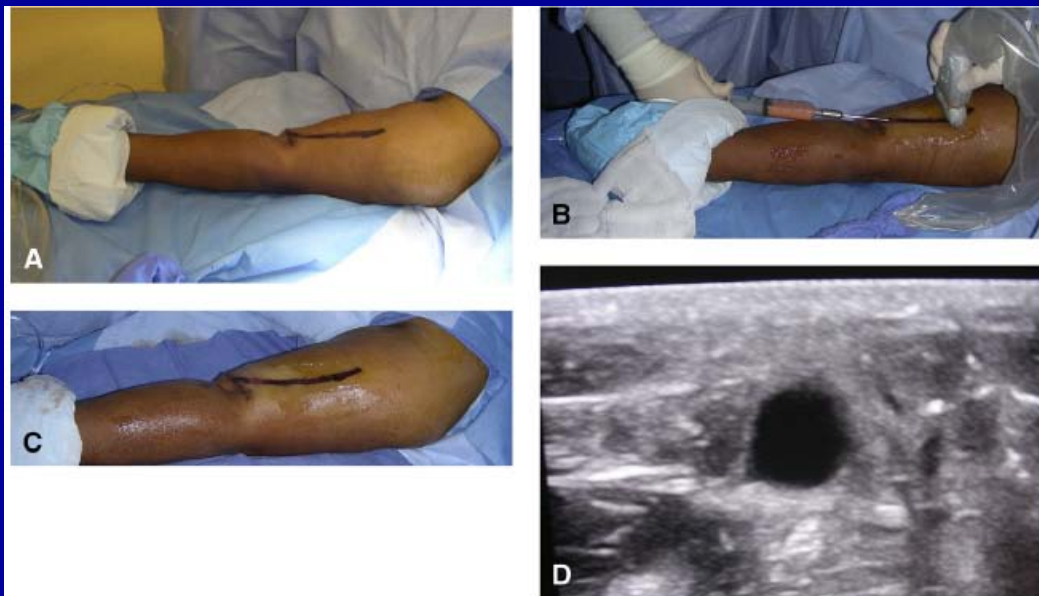
# VASCULAR AND ENDOVASCULAR TECHNIQUES

Thomas L. Forbes, MD, Section Editor

## Superficialization of arteriovenous fistulae employing minimally invasive liposuction

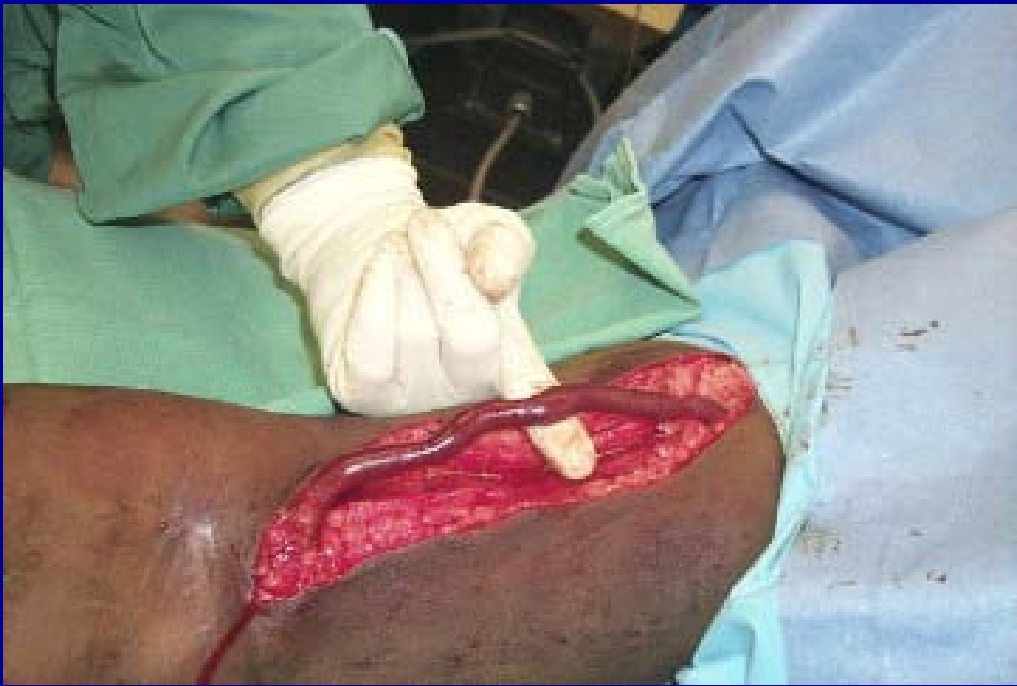Marlin Wayne Causey, MD, Reagan Quan, MD, Adam Hamawy, MD, and Niten Singh, MD, *Tacoma, Wash*

Superficialization of arteriovenous fistulae allows for improved dialysis access allowing for prolonged utilization and more efficient dialysis treatment. Multiple methods are described for superficializing arteriovenous fistulae, and minimizing the surgical intervention is advantageous for patient recovery and potentially improved outcomes. We describe a novel technique of superficialization of an upper extremity arteriovenous fistula employing ultrasound-guided liposuction. This article describes the suction lipectomy technique and the tools necessary for superficialization of an upper extremity arteriovenous fistula. (*J Vasc Surg* 2010;52:1397-400.)

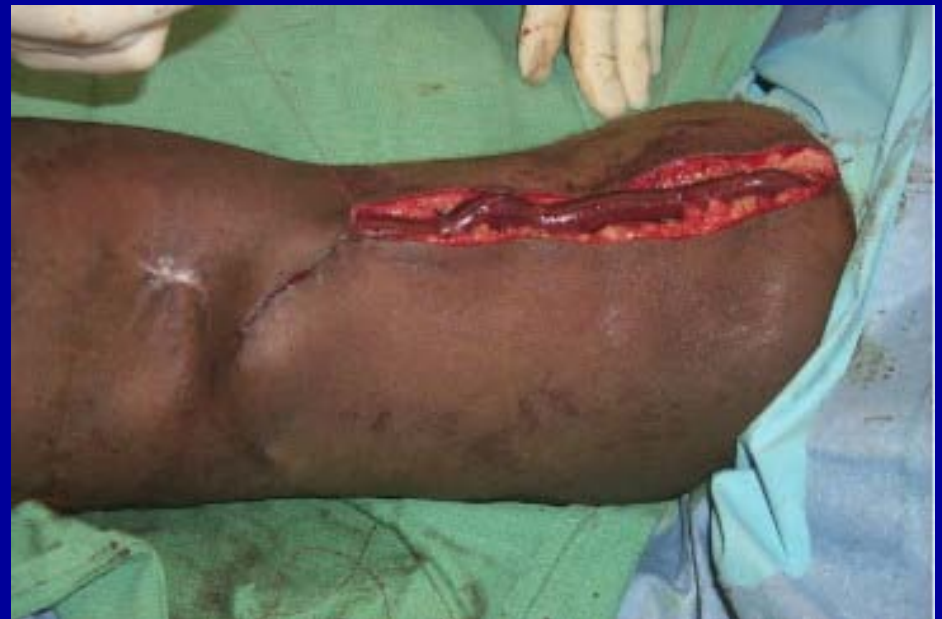



## Fistula Elevation



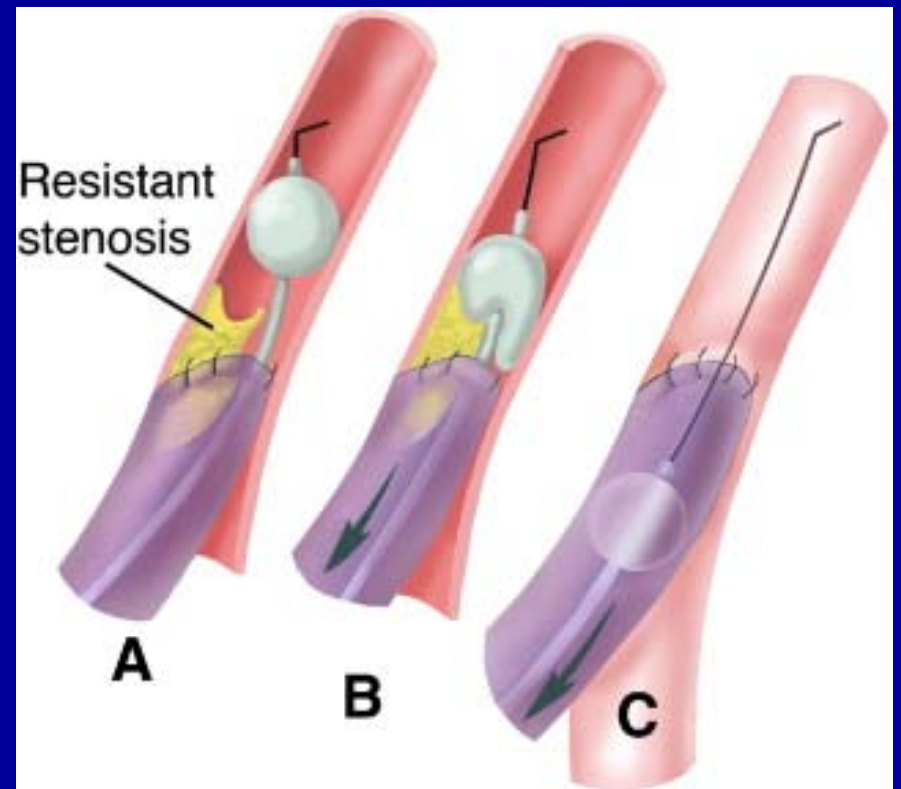
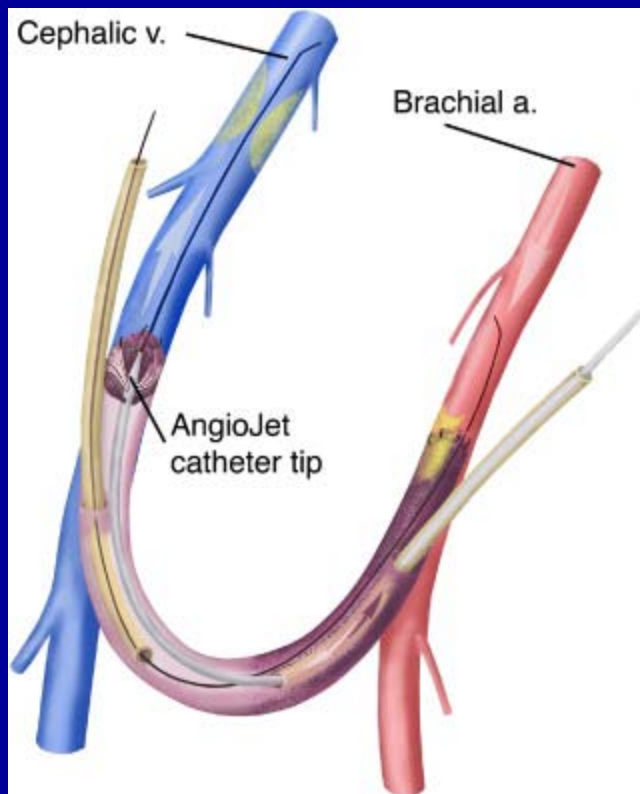
- **Exposure**
- **Mobilization**
- **Elevation**



# Complications of Hemodialysis Access

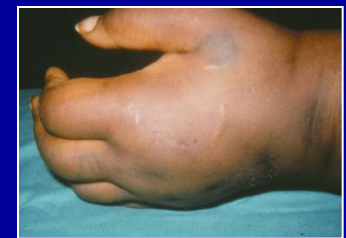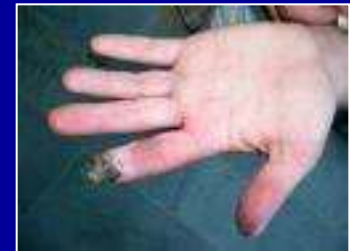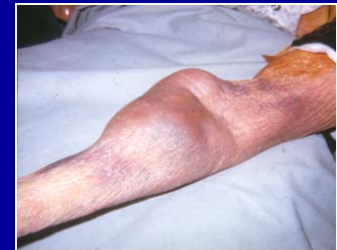- Thrombosis
- Hemodynamic complications
  - Congestive Heart Failure
- AV access steal syndrome
- Ischemic monomelic neuropathy
- Carpal tunnel syndrome
- Noninfectious fluid collections
  - Hematoma, seroma, lymphocele
- Venous hypertension
- Aneurysm / pseudoaneurysm
- Infection

# Percutaneous Thrombectomy



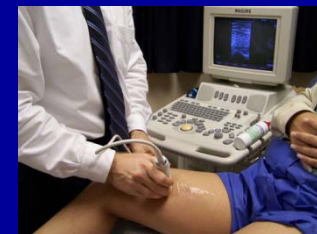# Noninvasive Evaluation of Dialysis Access Complications

- Perigraft fluid collection
- Pseudoaneurysm
- Arm swelling
- Steal syndrome
- Poor fistula maturation



# Duplex Assessment of AV Access Complications

- Palpable focal mass in graft (pseudoaneurysm)
- Evaluation of access dysfunction if physical exam or pressure measurements suggesting graft stenosis (monitoring v surveillance)
- Evaluation of ischemia / steal syndrome
  - volume flow measurements
  - flow reversal in distal artery
- Evaluate central veins if arm swelling



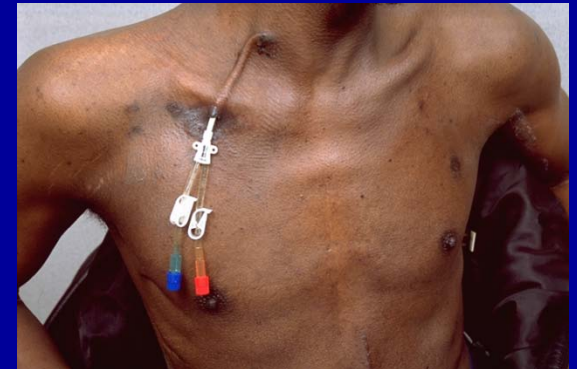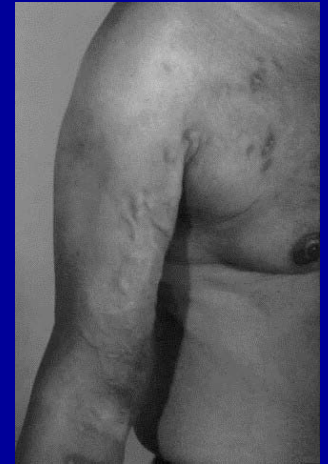# Hemodynamic Complications

## Congestive Heart Failure

- Flow rates  $> 600$  cc/min may be required for adequate hemodialysis
- High flow fistula ( $>2$  L/min) can cause heart failure
- Prevention
  - Step grafts to restrict flow to 300-400 ml/min
  - Limit size of anastomosis for AV fistula
- Banding of high flow fistulas to reduced hemodynamic complications

# Venous Hypertension

- Swelling of entire extremity after construction of AV fistula almost always indicates a previously unrecognized major central venous stenosis or occlusion.
- Frequently related to previous central venous catheters.



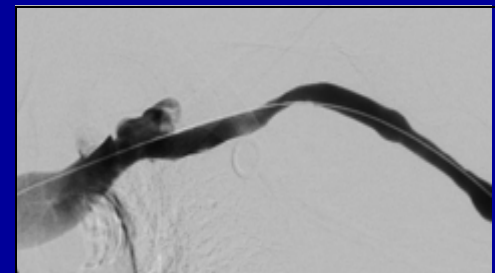
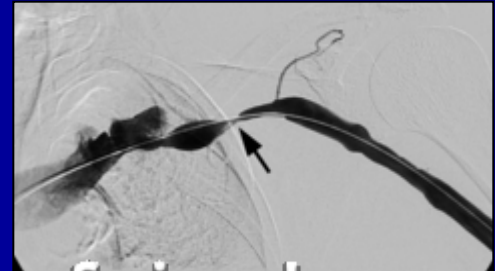# Venous Hypertension Treatment

- Conservative
  - Limb elevation
  - Compression therapy
- Ligation of functioning access
- Vein angioplasty with or without stent
- Central venous reconstruction
  - Bypass of occluded vein
  - Jugular turndown procedure

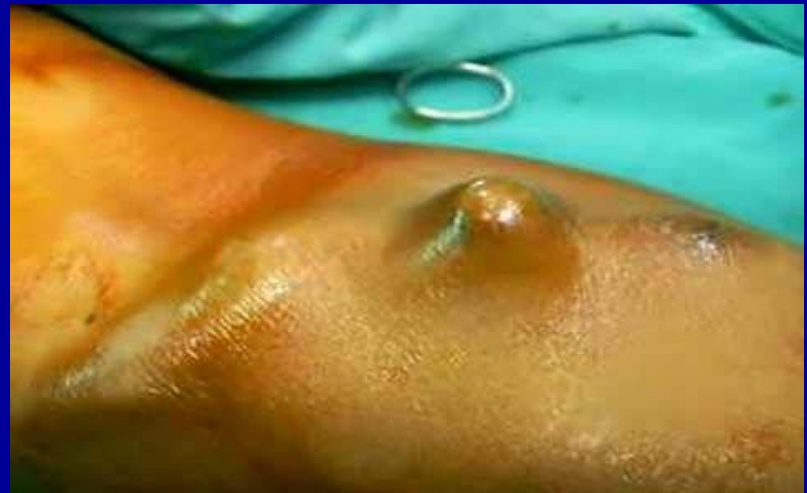
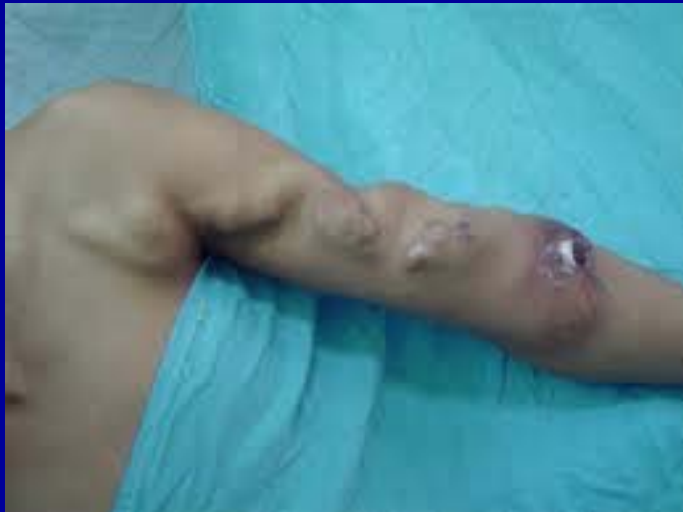
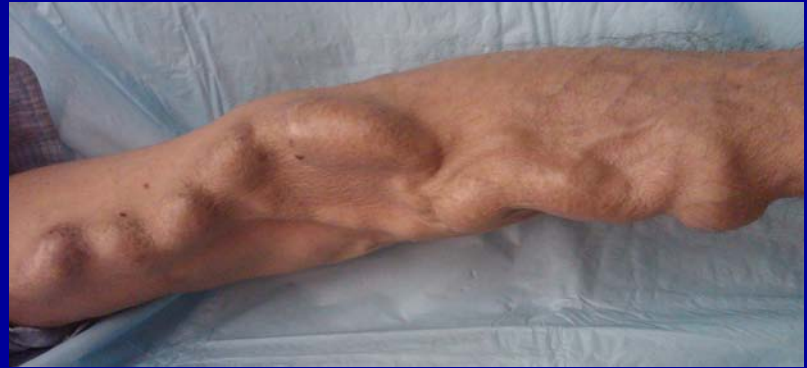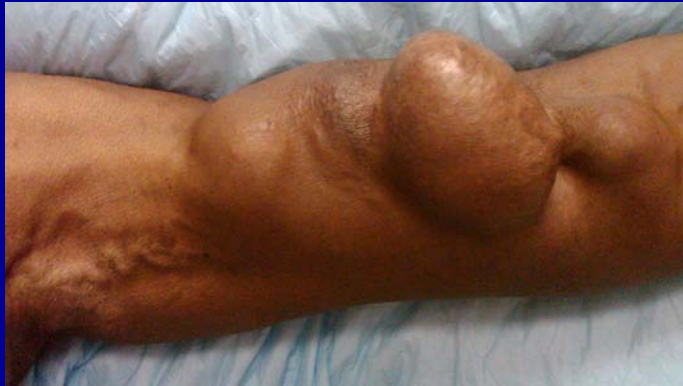# Cephalic Arch Stenosis

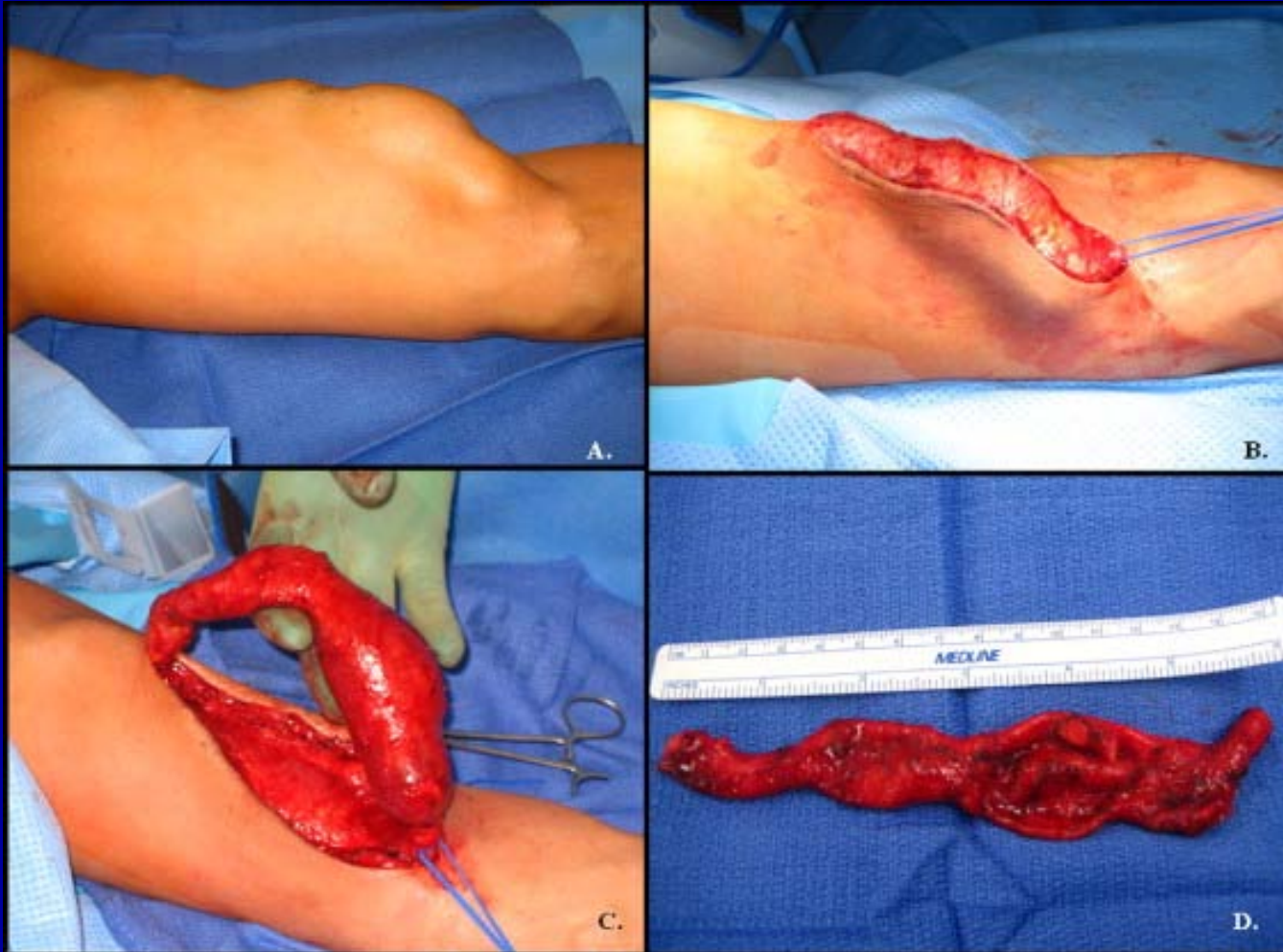- Functional stenosis of cephalic vein at cephalic arch (junction with subclavian vein)
- May lead to increased venous pressures and aneurysmal dilatation of fistula
- Treatment options
  - Endovascular (angioplasty, stent)
  - Open surgical repair / transposition



# AV Fistula Aneurysm

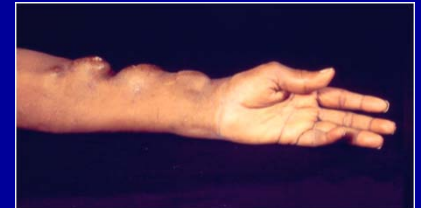


# Repair of AV fistula aneurysm



# Pseudoaneurysm of AV Graft

- Weakness in wall of prosthetic graft from repeated needle sticks
- Needle sticks heal with fibrous tissue replacing segments of the prosthesis with collagen, expands under pressure
- Treatment
  - Covered stent (can access through stent)
  - Segmental repair or replacement



# **Differential Diagnosis of Hand Dysfunction Following AV Access**

- **Vascular steal syndrome**
- **Ischemic monomelic neuropathy**
- **Neurological complications of axillary block anesthesia or patient positioning**
- **Carpal tunnel syndrome or other peripheral nerve compression**
- **Postoperative pain**
- **Functional deficit secondary to surgical trauma, venous hypertension or postoperative swelling**

# Incidence of Ischemia in Patients with Arteriovenous Access (4853 procedures) (Zanow, et al.)

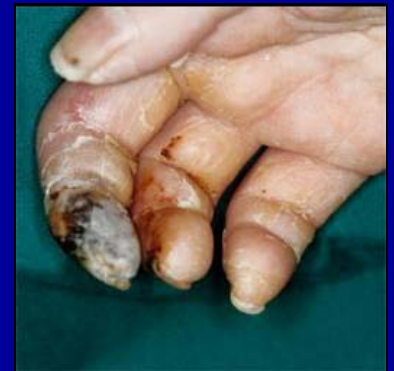Location	Incidence	# of Procedures
Snuffbox AVF	0.0%	59
Wrist AVF	0.3%	1999
Elbow AVF	1.8%	1870
--brach-cephalic	0.9%	1345
--brach-basilic	3.7%	274
--brach-ceph/bas	5.2%	251
PTFE grafts	2.2%	925

# Onset Time of Ischemia in Patients with Arteriovenous Access (Zanow, et al.)

<b>Ischemic Onset Time</b>	<b>AV Fistula (126)</b>	<b>AV Graft (62)</b>
<b>Acute (<math>&lt; 30</math> days)</b>	<b>29.4%</b>	<b>37.1%</b>
<b>Subacute (30 - 365 days)</b>	<b>23.8%</b>	<b>43.6%</b>
<b>Chronic (<math>&gt; 1</math> year)</b>	<b>46.8%</b>	<b>19.3%</b>

# Treatment of AV Access Related Ischemia

- If access flow rate **higher** than necessary
  - Restrict flow
    - Banding
    - Interpose smaller graft segment
- If flow **adequate**
  - Distal revascularization interval ligation
  - Proximalization of arterial inflow
- If ischemia **severe**
  - Ligate access
  - Search for new site



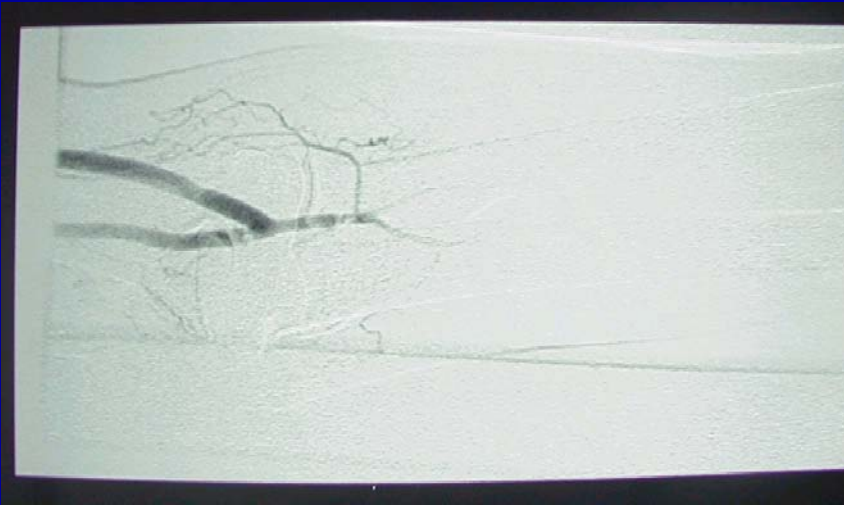


# Techniques to Correct Access Related Ischemia

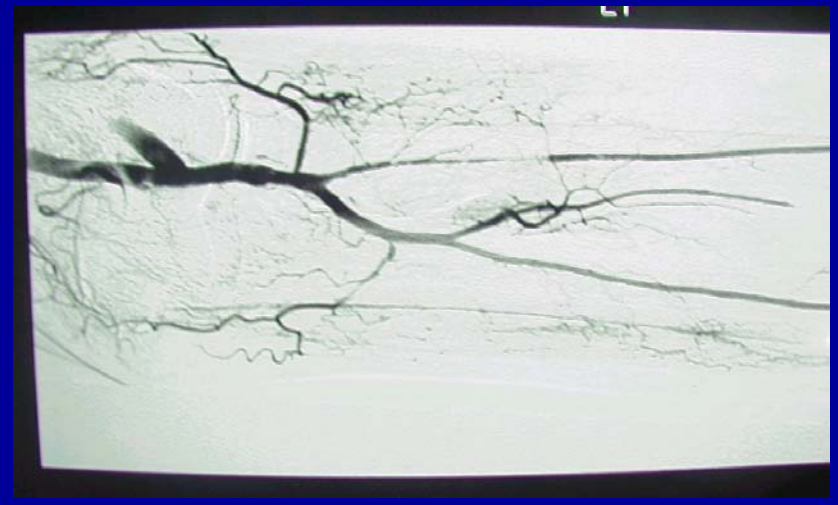
- Plication or banding (must create stenosis of greater than 60% to achieve significant flow reduction)
- Ligation distal vein or branches below end to side anastomosis
- Ligation distal artery to create end to end anastomosis and eliminate flow reversal
- Distal revascularization interval ligation (DRIL)
- Proximalization of arterial inflow
- Ligation access, search for alternate sites

# Arterial Steal

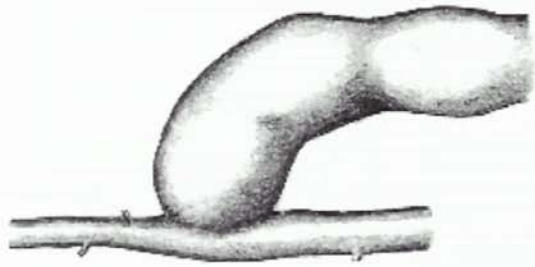
Before AV Graft  
Compression



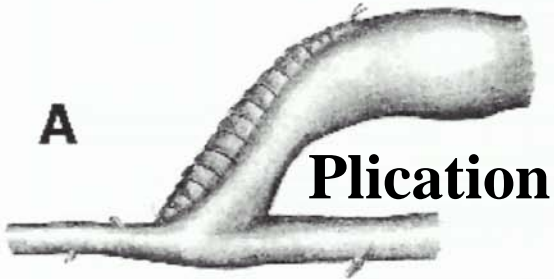
After AV Graft  
Compression



# Steal Syndrome Banding




**A**




**Plication**

**B**

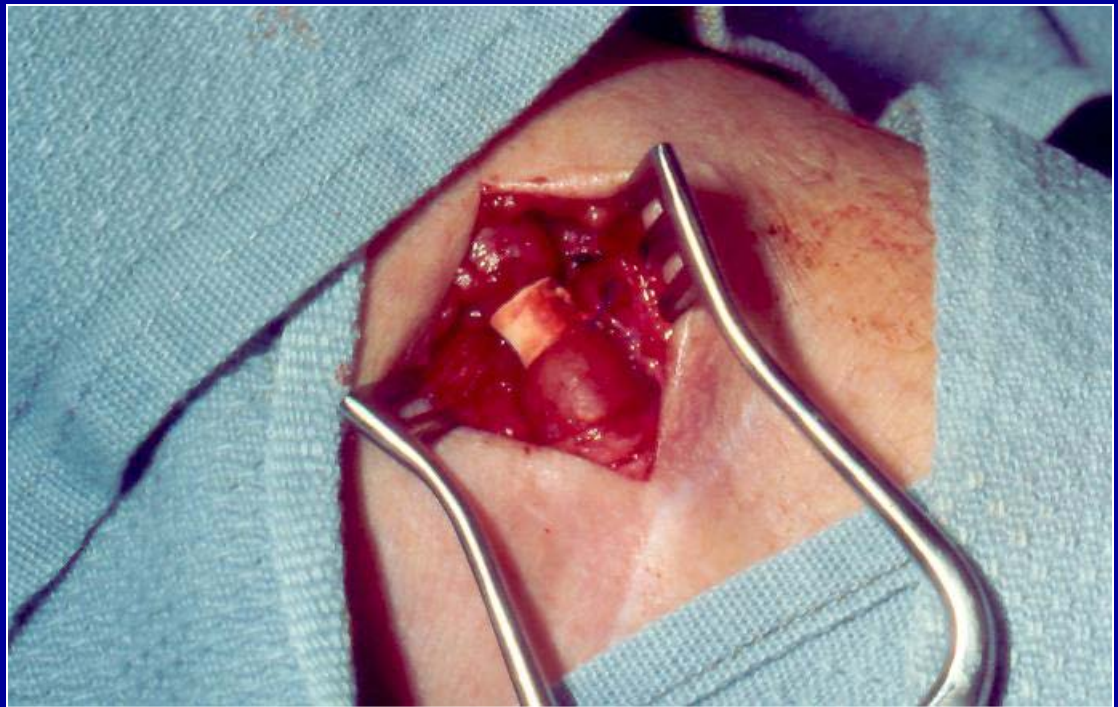


**Interposition**

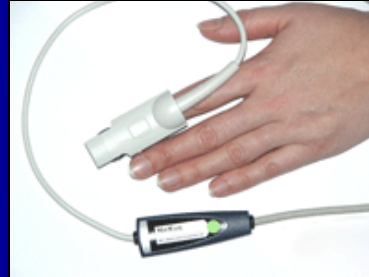**C**



**Banding**

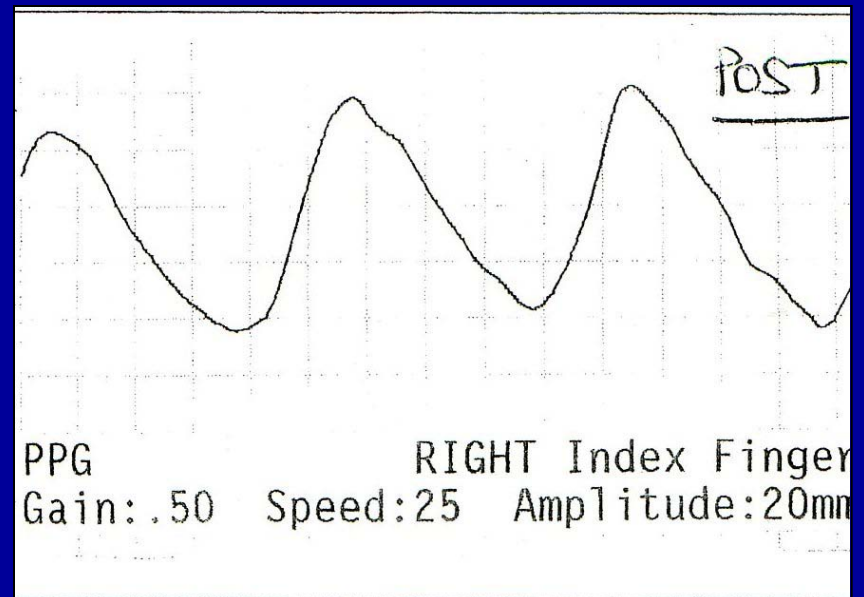
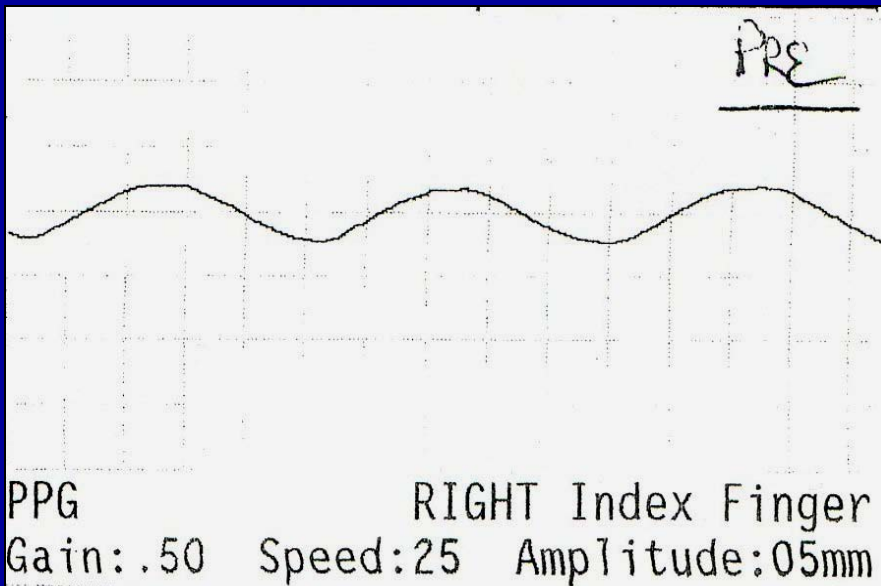


# PHOTOPLETHYSMOGRAPHY



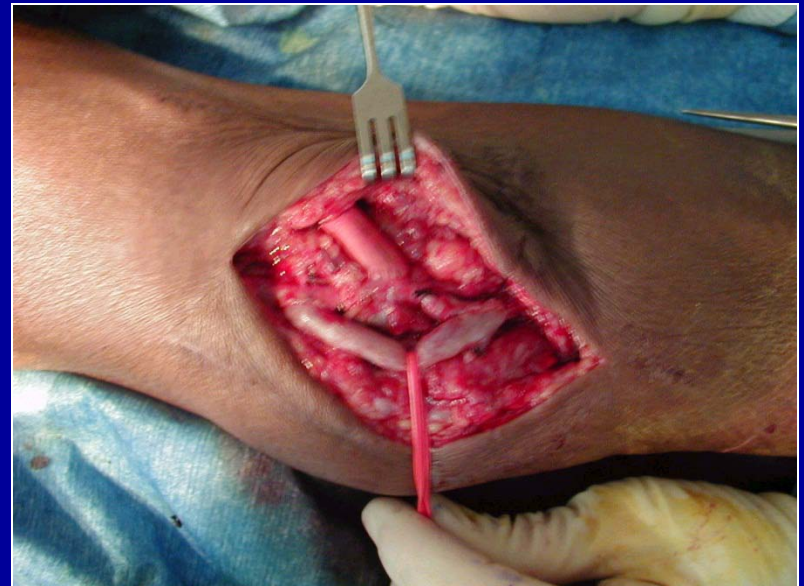PRE

POST



# Distal Revascularization Interval Ligation

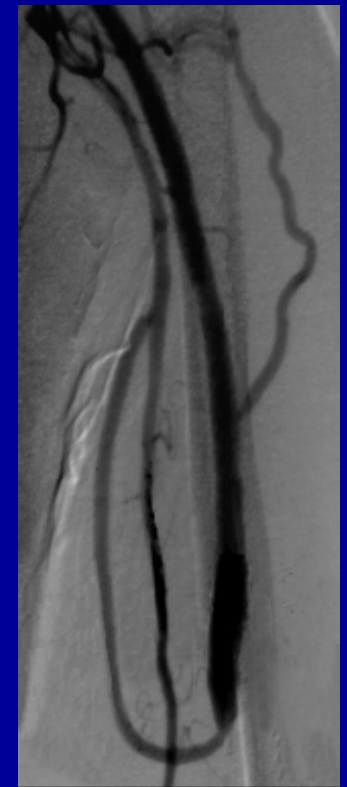
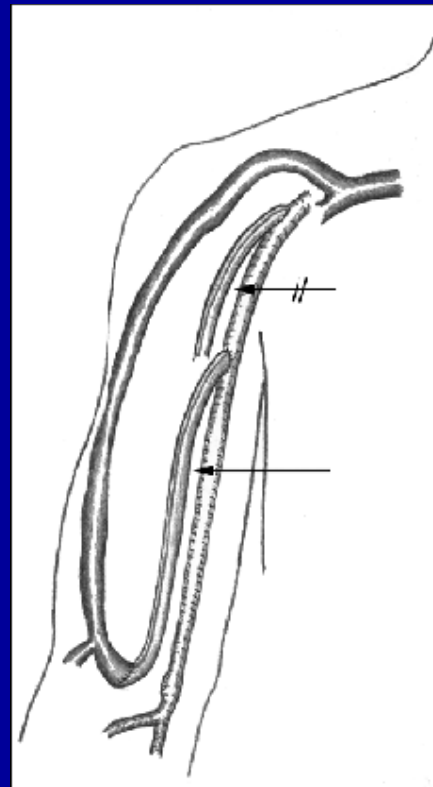
- Reliably restores antegrade flow to ischemic limb
- Eliminates potential physiologic pathway for steal mechanism
- Maintains continuous dialysis access in difficult patients



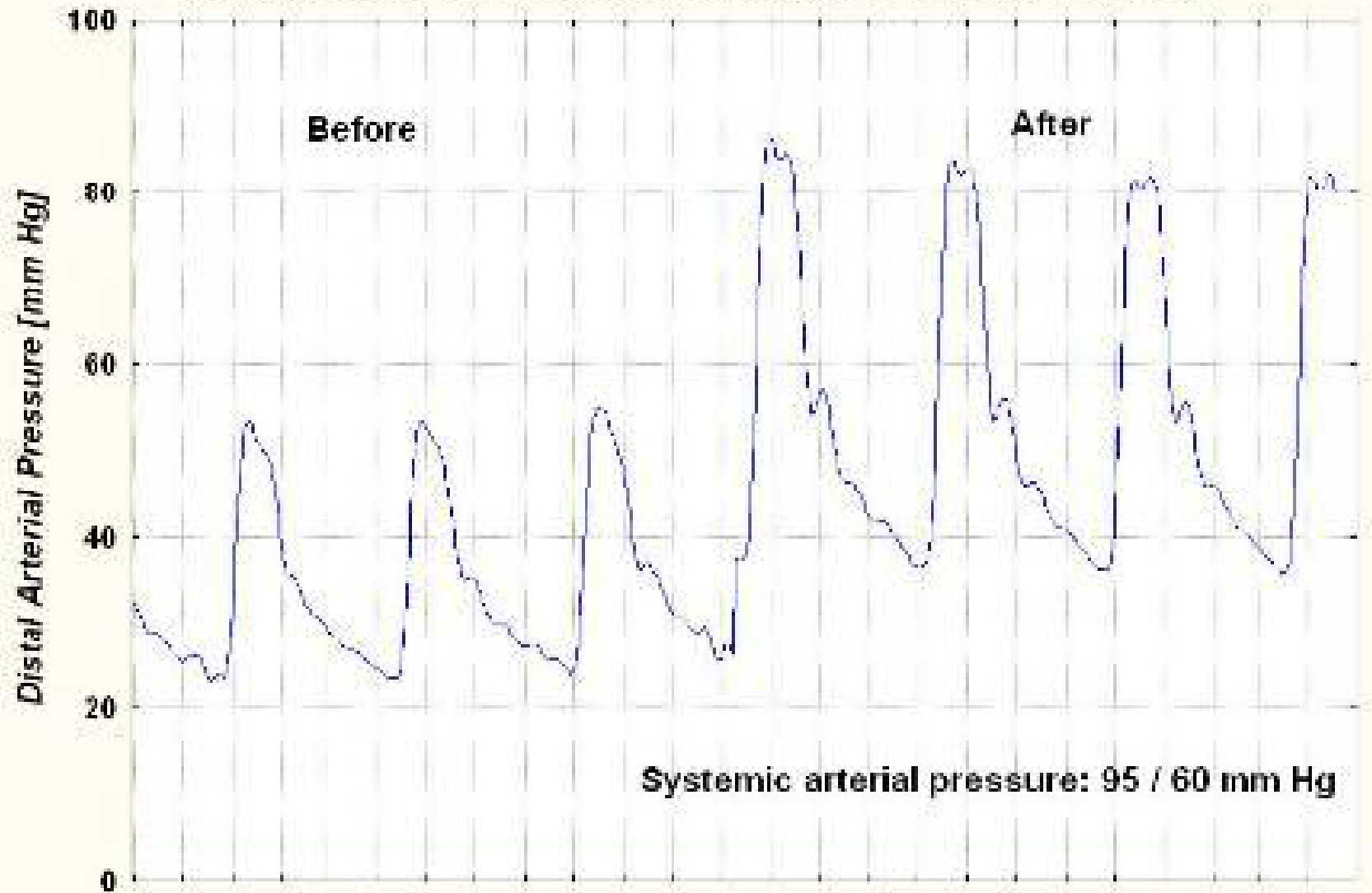
# Proximalization of the arterial inflow: A new technique to treat access-related ischemia

J Zanow, U Kruger, H Scholz  
J Vasc Surg, 43:1216-1221, 2006

- Effective in treating access related ischemia
- Does not sacrifice natural arterial continuity
- Alternative to DRIL

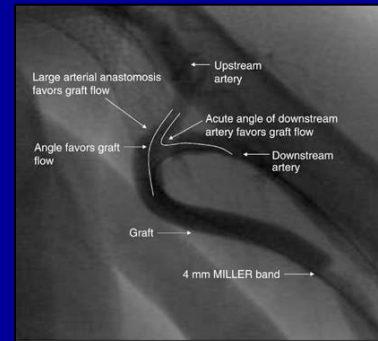


# Pressure of radial artery before and after Proximal Feeding of Elbow AV Fistula by 4 mm graft to proximal brachial artery

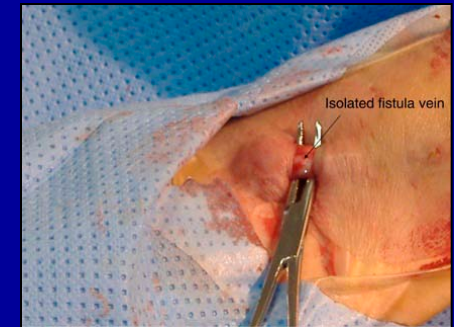


# Minimally Invasive Limited Ligation Endoluminal-assisted Revision (MILLER) for treatment of dialysis access-associated steal syndrome

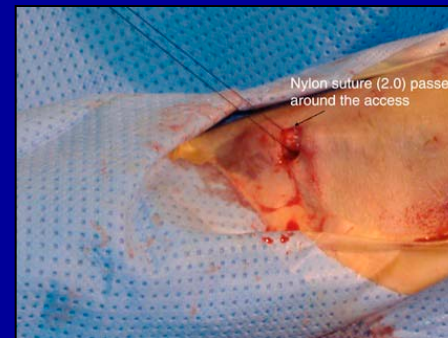
- Small (1-2 cm) skin incision
- 4-5 mm endoluminal balloon
- Standardizes desired reduction of inflow size



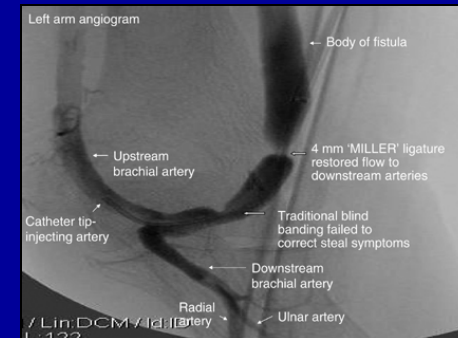
Fistulogram



Exposure



Limited Ligation

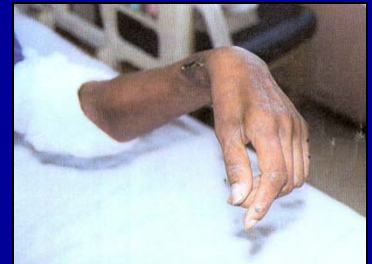

Completion



# Ischemic Monomelic Neuropathy

- Uncommon and potentially devastating complication of brachial based AV access procedure.
- Diabetes and female gender predominate
- Acute and often irreversible dysfunction of radial, median and ulnar nerves producing claw hand deformity
- Absence of severe tissue ischemia in affected extremity differentiates ischemic monomelic neuropathy from vascular steal.



# Ischemic Monomelic Neuropathy

- Early diagnosis and intervention with access closure recommended in patients with available alternative access sites.
- Recovery is at best unpredictable and even with appropriate management strategies and early intervention, patients may be left with a significant clinical deficit

	<b>Vascular Steal Syndrome</b>	<b>Ischemic Monomelic Neuropathy</b>
<b>Onset</b>	<b>Insidious</b>	<b>Immediate</b>
<b>Diabetes</b>	<b>++</b>	<b>++++</b>
<b>Sex</b>	<b>Variable</b>	<b>Female&gt;Male</b>
<b>Access Location</b>	<b>Wrist, forearm, upper arm</b>	<b>Forearm, brachial artery based</b>
<b>Affected Tissue</b>	<b>Skin&gt;muscle&gt;nerve</b>	<b>Nerve (multiple)</b>
<b>Clinical Ischemia</b>	<b>Severe</b>	<b>Mild</b>
<b>Radial Pulse</b>	<b>Absent</b>	<b>+ / -</b>
<b>Digital Pressure</b>	<b>Markedly decreased</b>	<b>Normal or slightly decreased</b>
<b>Reversibility</b>	<b>Variable</b>	<b>Poor</b>
<b>Treatment Options</b>	<b>Access revision (DRIL, banding)* / Ligation</b>	<b>? Access closure</b>

# Conclusions

- Fistula first and KDOQI initiatives mandate performance of more autogenous access
- Goals are reachable but with potential sequelae of decreased fistula maturation rates and increased catheter usage
- Fistula first should not be fistula at all costs – primary AV graft in selected patient populations
- Aggressive surveillance and intervention for immature or failing fistulas is recommended

Thank you

